

## PROTECTIVE EFFECTS OF AQUEOUS LEAF EXTRACT OF *CADABA FARINOSA* ON HISTOLOGY OF THE GASTROINTESTINAL TRACT OF ADULT WISTAR RATS

<sup>1</sup>A Perede, <sup>2</sup>A. Aisha, <sup>2</sup> A.A Musa, <sup>3</sup>A. Khadijat, <sup>3</sup>K Hauwa, <sup>3</sup>S.M Gamde.

<sup>1</sup>Usman Danfodiyo University Sokoto, Department of Histopathology

<sup>2</sup>Usman Danfodiyo University Teaching Hospital Sokoto. Department of Histopathology, Sokoto. Nigeria

<sup>3</sup>Hospital Service Management Board, Department of Medical Laboratory Science, Sokoto Nigeria

---

**ABSTRACT:** *Protective effects of phytochemicals offer notable prospects in exploring new therapeutics. Herbs are effective treatments of Peptic ulcer diseases than synthetic drugs. Most synthetic drugs cause adverse effects including impotence and hematopoietic disorders on chronic usage. Current treatments mainly targets potentiation defensive system of gastrointestinal tract with lowering acid secretion. Cadaba farinosa is a flowering plant in the Capparidaceae family with high ethno-medicinal value, referred as 'mucosae plant medicine'. Traditionally, it's used for treatments of diarrhoea, dysentery and intestinal helminthes. This study investigated cytoprotective effects of oral administration of aqueous leaf extracts. Sixteen adult Wistar rats were divided into four groups of four rats. Group 1 is control. Extract administered to groups (2, 3 and 4) at 100, 200 and 300 mg/kg, showed increased goblet cells secreting mucus; a major lining epithelia vulnerable to cellular compartment. Hence, phytochemicals offers notable prospect for exploring new therapeutics.*

**KEY WORDS:** *Cadaba farinosa, Leaf, Gastrointestinal tract, Goblet cells, Mucus, Epithelia.*

---

### INTRODUCTION

Phytochemicals (plant chemicals with protective or disease preventive activity) offer a notable prospect for the exploration of new varieties of therapeutics [1]. According to reports, medicinal plants are more effective in the treatment of peptic ulcer compared to synthetic drugs [2,3,4]. Peptic ulcers are common gastrointestinal disorders affecting the global population [5]. The ulcers are characterized by inflamed lesions of the mucosa and tissues that protect the gastrointestinal tract. The most common types of peptic ulcers are gastric and duodenal ulcers. The formation of peptic ulcers depends on the presence of acid and peptic activity in gastric juice plus a breakdown in mucosal defences. Acute peptic ulcers involve tissues down to the depth of the sub-mucosa, and the lesions may be single or multiple. Chronic peptic ulcers penetrate through the epithelial and muscle layers of the stomach wall [6,7]. Currently, the prevention or cure of peptic ulcers is one of the most important challenges confronting medicine nowadays [5]. Several numbers of synthetic drugs available for treatments of peptic ulcer produces adverse reactions including impotence, gynecomastia, and hematopoietic disorders upon chronic usage [2,3]. Due to these toxicological effects, a current treatment for peptic ulcers mainly targets potentiation of the defensive system of gastrointestinal tract along with lowering of acid secretion [5]. However, there is limited information on the cytoprotective mechanisms phytochemicals elicits there functions.

*Cadaba farinosa* Forsk is a flowering plant in the Capparaceae or Capparidaceae family. Its natural habitat is tropical or subtropical regions throughout the world. Folkloric medicine, Capparidaceae proved to be one of the many medicinal plants that are of high ethno-medicinal importance [8]. *Cadaba farinosa* is known as Indian Cadaba in English and the local names in Arabic, Fula and Hausa are Suraya, Baggahi and Bagayi respectively [9]. In folklore medicine, the plant is reported as 'mucosae medicine' that is used among several biological activities for the treatments of gastric and duodenal ulcers [1,10]. The stem bark and leaf are used in folklore remedies as purgative among natives of North-Eastern Nigeria [11]. Decoctions are externally applied to fresh wounds to prevent sepsis, thereby assisting in wound healing [8]. It is also popular among the people of Nigeria for anti-oxidative and cytotoxic properties [11]. The leaves are used as aperients and stimulant [8]. Other physiological and pharmacological applications include treatments of gastrointestinal parasites, diarrhoea and dysentery [1]. The roots and leaves are reportedly used in the treatments of coughs and rheumatism [12]. It analgesic and anti-inflammatory effects are also reported [4]. Despite the presence of several synthetic anti-peptic drugs in pharmaceutical stores, screening for new anti-peptic sources from natural plants is still attractive.

## MATERIALS AND METHOD

### Plant Collection and Identification

The fresh leaves of *Cadaba farinosa* was collected from a natural habitat in Faculty of Pharmaceutical Science, Usmanu Danfodiyo University Sokoto, Nigeria. The leaves was identified and authenticated at the herbarium unit of Pharmacognosy with voucher number PCG/UDUS/CAPP/0002.

### Preparation of Leaf Extraction

The leaves of the plant were collected and shaded to complete dryness. The dried plant were pulverized with mortar and pestle into powder form and stored in polythene bag for safety. 100g of the powder was macerated in 300mL of water at room temperature for 24 hours. The solution was filtered with Whatmann's filter paper to obtain particle free filtrates that was evaporated to dryness at 45°C in water bath [13].

### Phytochemical Analysis

Qualitative screening of some phyto-compounds was performed on the leaves extract using the standard methods [14,15,16].

**Test for reducing sugars** (Fehling's test): To about 2ml aqueous solution of the extract in a test tube was added 5ml mixture of equal volumes of Fehling's solution I and II and boiled in a water bath for about 2 minutes. The test tube was observed for brick-red precipitate.

**Test for Tannins** (Ferric chloride test): To about 2ml of the aqueous solution of the extracts was added few drops of 5% Ferric chloride solution (light yellow). The occurrence of blue-black colour shows the presence of gallic tannins and a green-black colour indicates catechol tannins. Braymer's test: Few drops of extract was treated with 10% alcoholic FeCl<sub>3</sub> solution and observed for bluish green colouration for tannins.

**Test for Saponins** (Frothing test): 3ml of the aqueous extract was mixed with 10ml distilled water in a test tube. The tube was stoppered and shaken vigorously for 5 minutes; it was allowed

to stand for 30 minutes and observed for honeycomb froth. Emulsion test: 3ml of the aqueous extract was dissolved in 10ml distilled water, stoppered and shaken vigorously for 5 minutes, after which 2-3 drops of olive oil were added and shaken again. Then it was put to rest for 30 minutes and observed for a layer of emulsion in between the aqueous layer and froth.

**Test for Cardiac Glycosides (Salkowski's Test):** The extract was dissolved in 2ml of chloroform. Concentrated sulphuric acid was carefully added to form a lower layer. A reddish-brown colour at interface indicated steroidal ring (that is aglycone portion).

**Test for Cardiac Glycosides (Leibermann's Test):** The extract was dissolved in 2ml of acetic anhydride and cooled well in ice. Concentrated sulphuric acid was added carefully. A colour change from violet to blue to green indicated presence of steroidal nucleus (that is aglycone portion of the cardiac glycoside)

**Test for Terpenoids/Steroids (Leibermann/Burchard's Test):** To 2ml of chloroform extract, 2ml of acetic anhydride and few drops of concentrated sulphuric acid were added in a test-tube. Blue-green ring between layers indicated steroids. Pink-purple ring indicated terpenoids.

**Test for flavonoids (Lead Acetate Test):** Extracts were treated with few drops of lead acetate solution. Formation of yellow coloured precipitate indicated the presence of flavonoids **Test**

**Test for flavonoids (Alkaline Reagent Test):** Extracts were treated with few drops of sodium hydroxide solution formation of intense yellow colour which became colourless on addition of dilute hydrochloric acid indicated the presence of flavonoids.

**Test for Alkaloids (Meyer's Reagent Test):** 1.0g of extract was dissolved in 5ml of 10% ammonia solution and extracted with 15ml of chloroform. The chloroform portion was evaporated to dryness and the resultant residue dissolved in 15ml of dilute sulphuric acid. Meyer's reagent test (Bertrand's reagent): 2.3 drops of Meyer's reagent was added to a portion of the acidic solution in a test tube and observed for an opalescence or yellow-white precipitate indicative of the presence of alkaloids.

#### **Test for Alkaloids**

Test for Alkaloids 1.0g of extract was dissolved in 5ml of 10% ammonia solution and extracted with 15ml of chloroform. The chloroform portion was evaporated to dryness and the resultant residue dissolved in 15ml of dilute sulphuric acid.

Meyer's reagent test (Bertrand's reagent): 2.3 drops of Meyer's reagent was added to a portion of the acidic solution in a test tube and observed for an opalescence or yellow-white precipitate indicative of the presence of alkaloids.

Dragendorff's reagent: 2ml of acidic solution in the second test tube was neutralized with 10% ammonia solution. Dragendorff's reagent was added and turbidity or precipitate was observed indicative of presence of alkaloids.

Wagner's Test: Few drops of Wagner's reagent were added to the acidic solution of the extract. A reddish- brown precipitate indicated the presence of alkaloids

**Test for Phlobatannins (Condensed Tannins)** Aqueous extract was boiled with 1% aqueous Hydrochloric acid. Red precipitate was indicative of phlobatannins.

### Experimental Animals

The animals used in this study were adult Wistar rats weighing 180-200g. They were raised in the Animal House of the Faculty of Pharmaceutical Science, Usmanu Danfodiyo University Sokoto, Nigeria. Authorizations for the use of laboratory animals were obtained from Ethical Committee for the use of laboratory animals, Department of Pharmacology, Usmanu Danfodiyo University Sokoto, Nigeria (Reg. No. (Reg. NO: PTAC/Cf/OT/004-18). The rats were kept in cages, supplied clean drinking water and fed *ad libitum* with standard commercial feed. All experimental procedures utilized were performed in accordance with the approval of the Institutional Animal Ethics Committee.

### Experimental Design

Table 1: Experimental Groups of Wistar Rats Treated with Aqueous Leaf Extract of *Cadaba farinosa* (n=4)

Experimental Groups	Daily Dose of ..... (mg/kg body weight)	Period of treatment (days)
Control	Distil water	28
I	100	28
II	200	28
III	300	28

### Tissue preparation

Microscopic tissue slides were processed using the standard procedures described by Tedong [17]. Paraffin sections of 4-5 $\mu$ m were stained with hematoxilin and eosin.

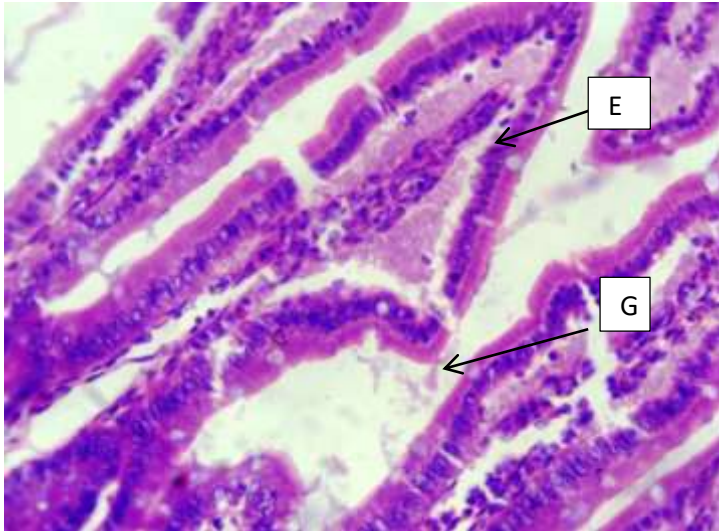
## RESULTS

Table 1: Physical Properties Leaf Extract of *Cadaba farinosa* Forsk

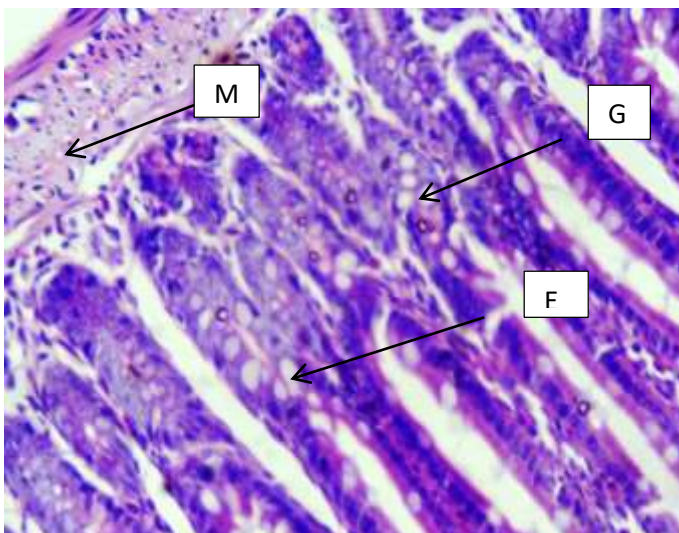
Plant part	Extract type	Texture	Colour
Leaves	Aqueous	Soft gel	Green

Table 2: Qualitative Analysis of some phytochemical constituents of Aqueous Leaf Extract of *Cadaba farinosa*

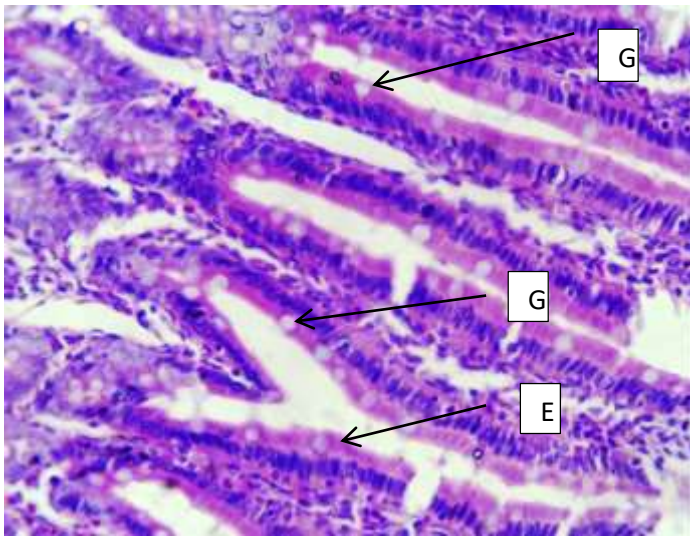
Phytochemicals	Status
Alkaloids	present
Flavonoids	present
Saponins,	present
Tannins	present
Cardiac glycosides	present
Proteins	present
Carbohydrates	present
Phenols	present
Steroids	present
Terpenoids	present
Diterpenes	present



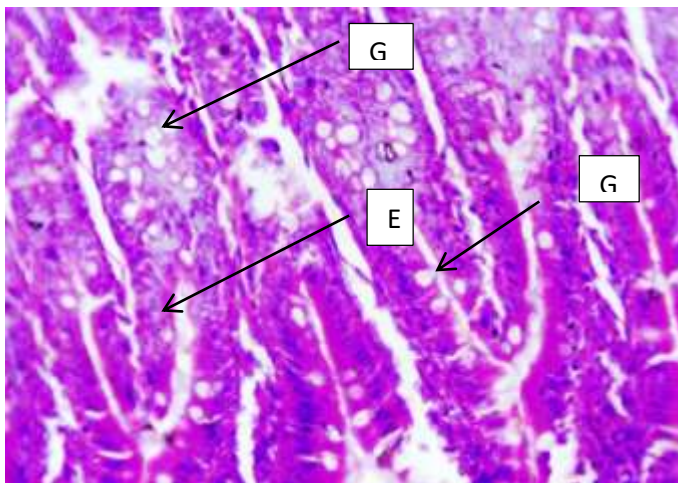
**Figure 1: Control group of experimental animals showing normal anatomical epithelial lining and few goblet cells**



**Figure 2: Animal treated with 100mg/kg of extract showed increase potentiation of goblet cells with normal epithelial lining and tissue compartments.**



**Figure 3: Animal treated with 200mg/kg of extract showed increase potentiation of goblet cells with normal epithelial lining and tissue compartments.**



**Figure 4: Animal treated with 300mg/kg of extract showed increase potentiation of goblet cells with normal epithelial lining and tissue compartments.**

## DISCUSSION

According to reports, medicinal plants are more effective in the treatment of peptic ulcer compared to synthetic drugs [2,3,4]. In folklore medicine, *Cadaba farinosa* is used among several biological activities for the treatments of gastric and duodenal ulcers [1]. Previous studies have shown oral administration of *Cadaba farinosa* having no effect on the behaviour, food and water intake, and mortality on experimental animals [18]. Similarly, organ weights of treated groups were unchanged. These results attest to the non-lethality of the plant at doses used since it is known that, reduction in body weight and internal organs are simple and sensitive indices of toxicity after exposure to a toxic substance [19]. Our result is similar to the aqueous leaf extract of *Passiflora edulis* that did not affect body weight of the experimental animals [20]. However, our results contravened the reported effects of *Garcinia kola* in Wistar rats that showed depressive effects on the animals appetite and water intake with resultant poor

feed utilization efficiency of rats in dose dependent manner [21]. Disparities of results could be due to variations in plant species or treatments duration.

One of the most important finding in this study was the proliferations of goblet cells observed in the gastrointestinal tract of rats treated with extract at 100, 200, and 300mg/kg for 28days compared to the negative control. The gastrointestinal tract is an amazing organ; it harbours more bacteria than there are cells in the human body, yet does not allow the bacteria to take over despite their rapid multiplication and could handle relatively strong hydrochloric acid without denaturing the stomach. The major protective mechanism of the vulnerable cellular compartment of the gastrointestinal tract is mucus lining the epithelia cells and the glycocalyx built by and around mucins. Although, the mechanisms of cytoprotective activity of mucus in the intestine may vary, uttermost is the defence line of the mucus layer. This suggests the cytoprotective effects of *Cadaba farinosa* and its integrity are important for the protection of colon epithelium and inhibiting activation of the immune system. Our previous studies have showed that aqueous stem bark of *Cadaba farinosa* possess anti-peptic activity [22].

## CONCLUSION

This study supports that *Cadaba farinosa* possesses cytoprotective effects on vulnerable cellular compartment of gastrointestinal tract. Further pharmacological and biochemical investigations are required to elucidate its mechanism of action.

## REFERENCES

- [1] Ibrahim S.I., Ameh D. A, Atawodi S. E., Umar I. A., Jajere U. M. and Mohammed S. Y. (2016). In vitro Inhibitory Effect of Methanol Leaf Extract of *Cadaba farinosa* on Carbonic Anhydrase Activity, *International Journal of Biochemistry Research and Review*, 11(4): 1-8.
- [2] Taju G, Jayanthi M, Abdul Majeed S (2011). Evaluation of Hepatoprotective and Antioxidant activity of Psidium guajava Leaf Extract against Acetaminophen Induced Liver Injury in Rats. *International Journal of Toxicology and Applied Pharmacology*, 1(2): 13-20.
- [3] Jainu M, Devi CSS (2005). Antiulcerogenic and Ulcer Healing Effects of Solanum nigrum (L.) on Experimental Ulcer Models: Possible Mechanism for the Inhibition of Acid Formation. *Journal of Ethnopharmacology*, 104: 156-163.
- [4] Mohammed Zewdu (2016). The Effect of Chronic Treatment of the Ethanolic Fruit Extract of *Embelia schimperi* on Blood Parameters, and Liver and Kidney of Rats. Addis Ababa. Ethiopia, 1-30.
- [5] Pahadiya Anitakumari Rambhai, S. S Sisodia (2018). Indian Medicinal Plants For Treatment of Ulcer: Systematic Review, *UK Journal of Pharmaceutical and Biosciences*, 6(6): 38-44.
- [6] Jamal A, Siddique A, Jafri MA (2006). A Review on Gastric Ulcer Remedies in Unani System of Medicine. *Pharmacology*, 5(2): 153-159. 3.
- [7] Brenner MG, Stevens CW (2006). *Pharmacology*, 2nd ed, Elsevier, New Delhi, 310-14
- [8] Umesh Telrandhe, Vaibhav Uplanchiwar (2013). Phyto-pharmacological Perspective of *Cadaba farinosa forsk.* *American Journal of Phytomedicine and Clinical Therapeutics*.1:011-022.
- [9] Orwa, C; A Mutua; Kindt R; Jamnadass R; S Anthony (2009). *Agroforestry Database: A Tree Reference and Selection Guide Version 4.0.*
- [10] Burkill, H.M. 1985. *The Useful Plants of West Tropical Africa. Volume1.*

- [11] Ezekiel J and Kadam T (2015). Phytochemical Analysis and Biological Assay of the Methanolic Leaf Extract of *Cadaba farinosa* Forsk (Capparidaceae). *International Journal of Advanced Research*. **3**:1368-1375.
- [12] Ken Fern (2014). Useful Tropical Plants. The database and code is licensed under a Creative Commons Attribution-NonCommercial ShareAlike 3.0 Unported License.
- [13] Majekodunmi O., Zany K., Olanyaga, I, Shi L and Melanhin J., (1996). Selective Toxicity Diterpene from *Euphorbia Poi sonic*. *Journal of Medicinal Chemistry*. **39**:1005-1008.
- [14] Sofowora, A. (1993). Medicinal and Traditional medicine in Africa. Second edition, Spectrum Books Limited, Ibadan, Nigeria. Pp. 130.
- [15] Evans, C. Williams (2009). Trease and Evans Pharmacognosy, 6th Edition. China: Saunders Elsevier.
- [16] Tiwari Prashant, Bimlesh Kumar, MandeepKaur, GurpreetKaur and HarleenKaur, (2011). Phytochemical Screening and Extraction. A review. *International PharmaceuticaScientia*, 1(1): 98- 106.
- [17] Tédong, L., Dzeufiet, P., Dimo, T., Asongalem, E., Sokeng, S., Flejou, J., Callard, P and Kamtchouing, P. (2007). Acute and Sub-chronic Toxicity of *Anacardium occidentale* Linn Leaves Hexane Extract in Mice. *African Journal of Traditional, Complementary and Alternative Medicines*, **4**:140-147.
- [18] Umesh B.T., Hemlatha S., Modi A., (2010). Pharmacognostic and Phytochemical Investigation of the Root of *Cadaba farinosa forsk*, *International Journal of Pharmacology and Biosciences*. **1**:1-13.
- [19] Witthawaskul P., Ampai P., Kanjanapothi D., Taesothikul N. (2003) Acute and subacute toxicities of the saponin mixture isolated from *Schejlera leucantha* Viguier. *J. Ethnopharmacol.*, **89**: 115-121.
- [20] Devaki E, U. Beulah, G. Akila, and V. K. Gopalakrishnan (2012). "Effect of Aqueous Extract of *Passiflora edulis* on Biochemical and Haematological Parameters of Wistar Albino Rats." *Toxicology International*, (19)1; 63-67.
- [21] Ekene E. N., Erhirhie Earnest O (2014). *Garcinia kola*: A Review Of Its Ethno medicinal, Chemical And Pharmacological Properties. *International Journal of Current Research and Review*. **6** (11): 1-7.
- [22] Gamde S.M, Umar M, Avwioro O.G, Muhammad A.A. (2019). Effects of Aqueous Stem Bark Extract of *Cadaba farinosa* on the Gastrointestinal Tract of Wistar Rats. Annual General Meeting and Scientific Conference. Association of Specialist Doctors in Academic, Pp.18.

## ACKNOWLEDGEMENT

We are thankful to the scholars whose articles are cited and included in references of this manuscript. We are also grateful to authors, editors and publishers of all those articles, journals and books from where the literature of this present work has been reviewed and discussed.