

Frontal Region Focal Meningioma Mimicking Ischemic Stroke: A Case Report and Review of the Literature

Abstract

Meningiomas typically present with gradual onset of symptoms but on rare occasions may present mimicking an ischemic stroke. The case of a 46-year-old homemaker with a right frontal region focal meningioma mimicking an ischemic stroke is presented here. A review of the literature was carried out, and the important role of radiological evaluation in resolving the diagnostic puzzle and various treatment options are also discussed.

Keywords: Embolic stroke, ischemic stroke, meningioma

Charles Oshevire Ayara, Tagbo Tobechukwu Marchie

Department of Radiology,
University of Benin Teaching
Hospital, Benin City, Nigeria

Introduction

Meningiomas are the most common benign intracranial tumors accounting for about 90% of all intracranial tumors.^[1] They arise from arachnoid cell rests of the meninges and have several sites of predilection, namely parasagittal, brain convexity, suprasellar, and sphenoidal ridge. Overall, the incidence is approximately 6–8/100,000 and meningiomas account for 13%–26% of primary intracranial tumors. Meningiomas are most common between the ages of 40 and 70 and are two to three times more prevalent in females than males except in children.^[1–4]

This case is presented to demonstrate that radiological investigations are useful for localizing brain tumors and knowing their extent by using computed tomography (CT) and magnetic resonance imaging (MRI) where available.

However, CT features of meningioma appear more reliable, and easy to detect, even among less experienced radiologists. Hence, the effort to document CT features of intracranial meningioma in our environment where CT machines are more readily available than MRI machines.^[1–4]

Case Report

OA is a 46-year-old homemaker. She presented at the Accident and Emergency Department of the University of Benin

Teaching Hospital, Nigeria, with a history of progressive weakness of the left half of the body and irrational talk of about 2-week duration. There was no history of total loss of consciousness, seizure, or trauma to the head or history of headache.

She was diagnosed as hypertensive before presentation at a private hospital and has been on antihypertensive drugs since then. The patient neither does smoke cigarette nor take alcoholic drinks.

Clinical examination revealed a well-nourished middle-aged woman. She was not febrile or jaundiced or pale. The blood pressure (BP) was elevated measuring 210/110 mmHg. The pulse was 82 beats per minute and regular, hence the suspicion of ischemic stroke. Neurological assessment showed that she was conscious but uttered some irrational speech from time to time. The respiratory, gastrointestinal, and genitourinary systems were essentially normal. A provisional diagnosis of right hemispheric ischemic cerebrovascular accident was made, and the patient was referred to the radiology department for a brain CT scan, to differentiate the type of ischemia, whether hemorrhagic or embolic stroke, since this will determine treatment protocol.

The CT scan showed a well-defined, extra-axial, broad-based hyperdense, intracranial mass in the convexity of the right frontal region. This mass enhanced brightly postcontrast injection. There was a hypodense area adjacent to the hyperdense mass, suggestive of massive surrounding edema from mass pressure.

How to cite this article: Ayara CO, Marchie T. Frontal region focal meningioma mimicking ischemic stroke: A case report and review of the literature. *J Radiat Med Trop* 2022;XX:XX-XX.

Submitted: 07-Apr-2022

Revised: 17-May-2022

Accepted: 21-Jun-2022

Published: ***

Address for correspondence:

Dr. Charles Oshevire Ayara,
Department of Anatomy, Faculty
of Basic Medical Sciences,
Bingham University, Karu,
Nigeria.

E-mail: ayaracharles74@gmail.com

Access this article online

Website: www.jrmt.org

DOI: 10.4103/jrmt.jrmt_4_22

Quick Response Code:



This is an open access journal, and articles are distributed under the terms of the Creative Commons Attribution-NonCommercial-ShareAlike 4.0 License, which allows others to remix, tweak, and build upon the work non-commercially, as long as appropriate credit is given and the new creations are licensed under the identical terms.

For reprints contact: WKHLRPMedknow_reprints@wolterskluwer.com

There was significant compression of the anterior horn of the right lateral ventricle by the mass and contralateral shift of the midline structures and the left lateral ventricle with moderate obstructive distension of the left ventricle. There was no erosion of the bones adjacent to the lesion [Figures 1-3].

A radiological diagnosis of an intracranial, extra-axial, space-occupying lesion was made with considerations of the following: First, meningioma; second, peripheral aneurysm, and last, angiomatous malformation. Time-based delay views were not able to show contrast clearance; hence, we excluded aneurysm and angiomatous malformation, thus leaving us with diagnosis of meningioma.

Based on this diagnosis, the patient was referred for neurosurgical management. She was worked up for surgery. A craniotomy was done during which a total tumor excision of the right frontal region mass lesion was done.

Histopathological examination of the frontal region tumor confirmed the presence of multiple sheets of glycogenated polygonal cells with abundant clear cytoplasm and round, uniform, bland-appearing nuclei consistent with clear-cell meningioma.

A postsurgical follow-up brain CT scan was done which showed that there was complete excision of the focal meningioma tumor in the right frontal lobe when compared with the presurgery CT findings. However, remnant of focal area of blood collection and surrounding cystic fatty cell collection of the necrotic tissue was noted. There was significant reduction in pressure effect from edema obliterating the anterior horn of the right lateral ventricle with contralateral shift of the midline structures [Figure 4].

The patient made good recovery, evident by the return of rational verbal communication and muscle power to the left half of the body. The patient is being followed up.

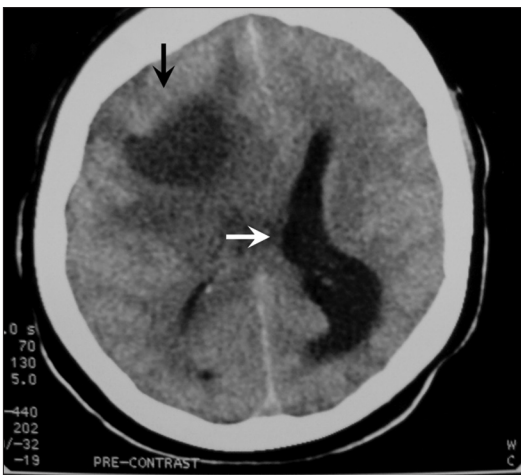

Figure 1: Unenhanced axial computed tomography image showing a hyperdense, broad-based lesion in the right frontal region (black arrow) with effacement of the ipsilateral lateral ventricle and with significant mass effect (white arrow)

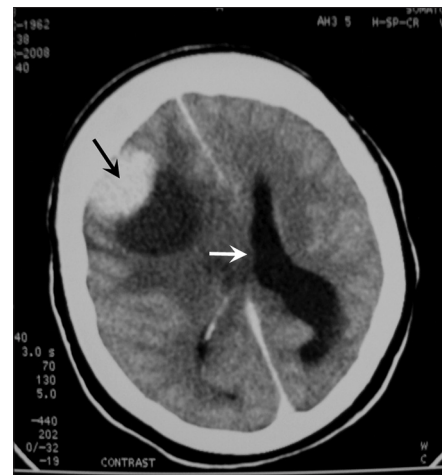

Figure 2: Contrast enhanced axial computed tomography image showing a brightly enhancing well-defined circumscribed lesion in the right frontal region (black arrow) with surrounding hypodense area suggestive of edema causing significant mass effect (white arrow)

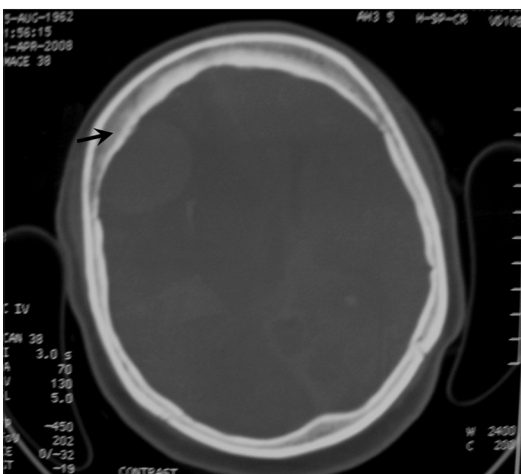


Figure 3: Bone window of axial computed tomography of the same patient in Figures 1 and 2 above. There is no erosion of the frontal bone or reactive hyperostosis adjacent to the lesion (black arrow)

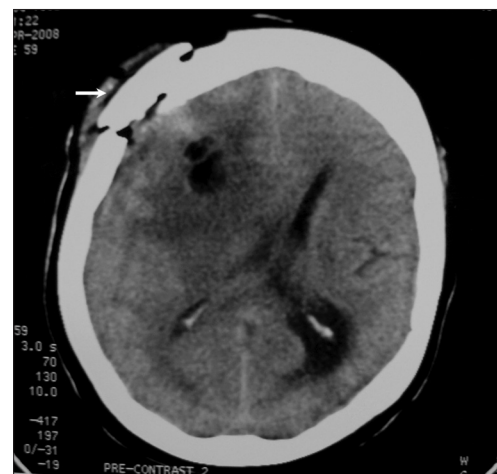

Figure 4: Postsurgical (total tumor excision) noncontrast axial cranial computed tomography imaging showing significant tumor removal but with residual mass effect. White arrow showing craniotomy site

Review of the literature

Meningiomas are the second most common brain tumors in adults and the most common tumors arising from meninges. The average incidence is 6–8 cases per 100,000 individuals, which has increased during the past 30 years due to the improvement of diagnostic imaging. However, they remain under-reported in our environment of practice in spite of available improved diagnostic modalities. Meningiomas are most common between the ages of 40 and 70 and are two to three times more prevalent in females than males.^[1-5]

Meningiomas produce clinical features as a result of mass effect within the brain in their victims. This effect may result in impairment of function, or features of raised intracranial pressure causing remarkable increase in BP and pulse rate, or may provoke either generalized or partial seizures depending on the location of the meningioma in the brain.^[6,7] Occasionally, meningiomas can mimic an ischemic cerebrovascular accident. In particular, skull base meningioma often involves an intracranial portion of the internal carotid artery^[8,9] and may compromise cerebral blood flow, thus resulting in transient cerebral ischemia.^[10,11] In an analysis of 106 verified cases of brain tumors, Gurova and Beliaev^[12] observed that one group of 51 patients presented with clinical picture similar to hemorrhagic stroke while another group of 55 cases showed features mimicking ischemic stroke. Ueno *et al.*^[13] reported the case of a 67-year-old female who had transient neurological deficits involving fainting and right-sided hemiparesis, in whom MRI confirmed a left-sided sphenoid ridge meningioma which had encased the internal carotid and middle cerebral arteries. The patient had no more symptoms after total surgical excision of the tumor.^[13] However, meningioma may coexist with elevated BP in the same patient; therefore, regular BP check should be carried out. It should be noted that increase pulse rate and elevated BP are found as common features of a raised intracranial pressure. The role of medical imaging in making a definitive diagnosis cannot be over emphasized in view of some similarities between brain tumors and cerebrovascular disease.^[13]

Radiological evaluation of a suspected case of intracranial space-occupying lesion can be done using plain film, CT, MRI, and angiography.^[14] MRI is the modality of choice and cornerstone for radiological diagnosis and follow-up of meningiomas, whereas CT is used when patients cannot undergo MRI.^[5] MRI is very sensitive in meningioma, and it typically presents as a well-circumscribed dural lesion with homogeneous enhancement to gadolinium,^[14] but it is greatly dependent on knowledge and exposure of the evaluator, since interrogation with different MRI sequences is required. Enhanced MRI may be considered superior in delineating extent of meningeal infiltrations. CT scan is superior in delineation of osseous involvement

and calcifications. Comparatively, none can be considered total superior in all ramifications. Hence, radiodiagnosis definition of lesion is mainly collaborative.^[15] On CT, meningiomas show as hyperdense lesions just above the brain density to very high density almost like bone. The tumors are generally well circumscribed, rounded, or lobulated. They take up contrast and enhance brightly; thus, the tumor site, size, and extent can be evaluated.^[16] Opinions differ greatly as to the role of angiography in cases of meningioma. However, when it is necessary, it involves selective internal and external carotid arteriography on one or both sides, sometimes with vertebral artery injection in addition. Cardinal angiographic findings include meningeal vessels supply to the tumor, persistent tumor blush, cortical vessel displacement, and compression. Preoperative embolization can also be performed with conventional angiography.^[16] Adequate clinical data can usually be obtained by means of MR angiography when preoperative embolization is not considered.

Significant progress has been made in the diagnosis and treatment of brain tumors in the past 15 years. This has largely been due to significant advances in radiographic imaging capabilities that have allowed for much earlier detection of disease, both new and recurrent cases.^[17]

The primary treatment of meningioma is surgery because cure is possible if a complete resection is accomplished. This involves complete removal of the tumor, dural origin, and involved skull bone,^[18] followed by histopathological examination to confirm the tumor as a meningioma.

Other treatment modalities of cranial meningioma include stereotactic surgery using the gamma knife or linear accelerator. Chemotherapy does not play a significant role in the treatment of meningioma.^[18]

Summary

The case of a 46-year-old homemaker with a right frontal meningioma mimicking an ischemic stroke has been presented, and a review of the literature was carried out. The important role of radiological evaluation in resolving the various diagnosis and treatment options have also been discussed.

Acknowledgement

I wish to acknowledge my consultants, Prof. Donald Nzeh, Prof. Tagbo Tobeckukwu Marchie, and all the staff of the Departments of Radiology, Neurosurgery, and Pathology of University of Benin Teaching Hospital, Benin City, Nigeria.

Declaration of patient consent

The authors certify that they have obtained all appropriate patient consent forms. In the form, the patient has given her consent for her images and other clinical information to be reported in the journal. The patient understands that

her name and initials will not be published and due efforts will be made to conceal identity, but anonymity cannot be guaranteed.

Financial support and sponsorship

Nil.

Conflicts of interest

There are no conflicts of interest.

References

- Sutton D, Stevens J, Miszkiet K. Intracranial lesions (1). In: Sutton D, editor. *Textbook of Radiology and Imaging*. 7th ed. London: Churchill Livingstone; 2002. p. 1755-7.
- Katharine J Drmmond, Jay-Jiguang Zhu, Peter McL Black. Meningiomas: updating basic science, management and outcome. *Neurologist* 2004;10:113-30.
- Lusis E, Gutmann DH. Meningioma: An update. *Curr Opin Neurol* 2004;17:687-92.
- White C, Smith P, Navoo P, Collie D. Meningiomas. *Lancet* 2003;363:1535-43.
- Ugga L, Perillo T, Cuocolo R, Stanzione A, Romeo V, Green R, *et al.* Meningioma MRI radiomic and machine learning: Systemic review, quality score assessment, and meta-analysis. *Neuroradiology* 2021;63:1293-304.
- Clarke CR. Neurological disease. In: Kumar P, Clark M, editors. *Clinical Medicine*. 5th ed. Toronto: WB Saunders; 2002. p. 1199.
- Ishikawa M, Nishi S, Aoki T, Takase T, Wada E, Oowaki H, *et al.* Predictability of internal carotid artery (ICA) dissectability in cases showing ICA involvement in parasellar meningioma. *J Clin Neurosci* 2001;8 Suppl 1:22-5.
- Bitzer M, Topka H, Morgalla M. Tumour-related venous obstruction and development of peritumoral brain oedema in meningiomas. *Neurosurgery* 1998;42:730-7.
- Fazi S, Barthelemy M. Petroclival meningioma mimicking the presentation of a transient ischemic attack. *Acta Neurol Scand* 1994;89:75-6.
- Kaur U, Chopra JS, Kak VK, Banerjee AK. Meningioma presenting as recurrent transient cerebral ischemia and intracranial hemorrhage. *Surg Neurol* 1982;17:120-2.
- Komotar RJ, Keswani SC, Wityk RJ. Meningioma presenting as stroke: Report of two cases and estimation of incidence. *J Neurol Neurosurg Psychiatry* 2003;74:136-7.
- Gurova EP, Beliaev VI. Stroke-like course of brain tumours. *Zh Nevropatol Psikhiatr Im SS Korsakova* 1984;84:650-4.
- Ueno Y, Tanaka A, Nakayama Y. Transient Neurological deficit simulating transient ischaemic attacks in a patient with meningioma: Case report. *Neurol Med Chir* 1998;38:661-5.
- Maggi I, Franceschi E, Tonsoni A, Nunno VD, Gatto L, Lodi R, *et al.* Meningioma: Not always a benign tumor. A review of advances in the treatment of meningiomas. *CNS Oncol* 2021;10:CNS72.
- Alnutayfi H, Masaad F, Hamdan A, AlneemAlkhidir N. Comparison between the CT and MRI for meningioma in the Brain in King Khalid University Hospital Riyadh K.S.A. *Int J Adv Res* 2019;7:1232-8.
- Jager HR, Caseiras GB, Rich MP. Benign and malignant intracranial tumours in adults. In: Grainger RG, Allison DJ, editors. *Diagnostic Radiology. A Textbook of Medical Imaging*. 5th ed. Philadelphia: Churchill Livingstone; 2008. p. 1285-6.
- Lyons MK, Vora SA. Brain tumors: Current issues in diagnosis and management. *Semin Neurol* 2007;27:312-24.
- Aldrich EF, Chin LS, DiPatri AJ, Eisenberg HM. Central nervous system tumours. In: Townsend CM Jr., editor. *Sabiston Textbook of Surgery: The Biological Basis of Modern Surgical Practice*. 16th ed. Toronto: W.B. Saunders; 2001. p. 333.