

Histological Integrity of the Testis of Adult Wistar Rats (*Rattus norvegicus*) Treated with *Garcinia kola*

Dare BJ¹, Chukwu RO¹, Oyewopo AO², Makanjuola VO¹, Olayinka PO¹, Akinrinade ID¹, Olaniyan TO³, Omotoso OD¹, Shafe MO³, Ogundele OM¹, Beremako OO¹ and Adeb MN¹

¹Department of Anatomy, Bingham University, P.M.B 005 Karu, Nigeria

²Department of Anatomy, University of Ilorin, P.M.B 1515, Ilorin, Nigeria

³Department of Physiology, Bingham University, Karu, P.M.B 005, Nigeria

Abstract

Garcinia kola has been confirmed for spermatogenic and tissue enhancing effect of testis in male wistar rats. This study was carried out to investigate the histological effect of ethanolic extract of *Garcinia kola* on Lead II oxide induced testicular damage. Thirty five (35) adult male wistar rats were randomly selected into seven (7) groups n=5. Group A received 0.5 ml saline solution, Group B received 100 mg/kg of *Garcinia kola* extract only, Group C received 5 mg/kg of Lead II oxide only, Group D₁ received 100 mg/kg of *Garcinia kola* extract and 5 mg/kg of Lead II oxide, Group D₂ received 200 mg/kg of *Garcinia kola* extract and 5 mg/kg of Lead II oxide, Group E received 500 mg/kg of vitamin E only and Group F received 500 mg/kg of vitamin E and 5 mg/kg Lead II oxide. Administration was done orogastrically daily for 2 weeks, animals were sacrificed 24 hours after the last administration by cervical dislocation and the testes excised following abdominal incision for histological observation using H/E stain. Slight degeneration of the germinal epithelium of the seminiferous tubule and abnormal widening of the interstitial space involving loss of Leydig were observed following the administration of Lead II oxide. However, Improvements in the testicular architecture were noticed in the rats treated with the *Garcinia kola* and the Vitamin E respectively thus histological integrity maintained.

Keywords: *Garcinia kola* seed; Vitamin E; Testes; Histological integrity; Wistar rats; Fertility

Introduction

Oxygen derived free radical result in reproductive impairment through oxidative damage to biomolecules in the testicular cell, with mitochondria being the main target of free radical attack [1]. Since oxygen radicals are needed for many metabolic and physiological processes, equilibrium between radical production and their antioxidant-linked inactivation is required to preserve health [1]. Thus, reproductive impairment is one of the results of an imbalance between free radical production and antioxidant defense [1]. Many studies have demonstrated the reproductive toxicity of lead [2-4]. During Lead exposure, it accumulates in the testes tissue in a dose dependent manner [2,3]. Lead toxicity induces a significant increase in apoptotic cell death in the seminiferous tubule of young growing rat [2]. It is also associated with disruption of spermatogenesis and histoarchitecture and lowered enzyme activities in the testes [3].

Conversely, several studies have shown that antioxidants preserve an adequate function of reproductive system against homeostatic disturbances caused by oxidative stress. Therefore, the protection of this system afforded by dietary antioxidant supplementation play an important role in order to achieve a healthy living [5,6].

The anti-oxidant property of *Garcinia kola* is attributed to its very high content of ascorbic acid [7]. Its mineral content includes potassium, calcium, magnesium, nitrogen and phosphorous. *Garcinia kola* seeds are the unique source of small quantities of kolaviron, a mixture of bioflavonoid GB-1, GB-2 and kolonflavone [8]. The antimicrobial properties of this plant are attributed to the benzophenone and flavanones [9].

Garcinia kola is used in many tropical countries to fight infectious diseases such as AIDS and the Ebola virus [10], in folklore remedies for the treatment of ailment such as liver disorders, hepatitis [10], diarrhea, open sores, parasites and laryngitis. The seed extract had been reported to prevent and relieve colic as well treat headache [11]. The plant has also found usefulness in the treatment of stomach ache, tumors, hemorrhoids, ulcers [12], dysentery, fever and gastritis. It was also

reported by Iwu, of the use of the plant for the treatment of jaundice, high fever, and as purgative [10].

Administration of *Garcinia kola* seed extract caused an increase in testosterone production in Sprague-Dawley rats which is thought to be due to its antioxidant properties [13]. Also, Adesanya et al. [14] confirmed the spermatogenic and tissue enhancing effect of *Garcinia kola* extract in male Wistar rats. *Garcinia kola* has been shown to inhibit smooth muscle activity; it relaxes the smooth muscles of the uterus and the intestine [15].

Therefore, this research project is aimed at studying the effects of *Garcinia kola* (Bitter kola) on induced lead II oxide testicular damage on wistar rats using histological parameters.

Materials and Methods

Experimental animals

Thirty five (35) Adult male Wistar rats weighing between 150-250 g were procured from the Animal House of the Nigerian Institute for Trypanosomiasis and Onchocerciasis, Kaduna Nigeria. The ethical approval on Animal act right was obtained from the Institutional Animal Care Committee of Bingham University Karu, Nigeria. They were kept in Laboratory for two (2) weeks of acclimatization and were fed on standard diet (Vital Feeds and Grand Cereals Ltd); Water was given ad libitum and maintained under standard conditions. The animal room was well ventilated with a temperature range of 25-27°C under

*Corresponding author: Dare BJ, Department of Anatomy, Bingham University, P.M.B 005 Karu, Nigeria, Tel: +2348077805474; E-mail: jdare_tolu@yahoo.com

Received October 31, 2012; Accepted November 25, 2012; Published December 05, 2012

Citation: Dare BJ, Chukwu RO, Oyewopo AO, Makanjuola VO, Olayinka PO, et al. (2012) Histological Integrity of the Testis of Adult Wistar Rats (*Rattus norvegicus*) Treated with *Garcinia kola*. Reprod Sys Sexual Disorders 1:113. doi:10.4172/2161-038X.1000113

Copyright: © 2012 Dare BJ, et al.. This is an open-access article distributed under the terms of the Creative Commons Attribution License, which permits unrestricted use, distribution, and reproduction in any medium, provided the original author and source are credited.

day/night with 12-12 h photoperiodicity. The rats were grouped into seven groups (5 rats each); Group A, B, C, D1, D2, E, and F respectively.

Extract preparation

Garcinia kola was obtained from Nyanyan market, FCT, Abuja and authenticated by the Biological Sciences Department, Bingham University Karu, Nigeria. The outer coats were removed and the seeds air dried. The dried seeds were grounded into fine powder; 300 g of the powder was soaked in 3000 ml of 70% ethanol for 24 hours and then filtered. The filtrate was concentrated to a semi solid form using the rotary evaporator. 60.7 g of the concentrate was obtained and dissolved in saline water for dosage preparation and media for administration and preserved in refrigeration throughout the experimental period.

Extract administration

The administration of the extract was totally by gavages, proper concentrations were administered by the use of metal oropharyngeal cannula. The administration of *Garcinia kola* extract was done daily at 0700 hour for period of Two (2) weeks. The Control Group A received 0.5 ml of saline solution while Group B received 100 mg/kg body weight of the extract only, Group C received 5 mg/kg body weight of Lead II oxide, Group D₁ received 100 mg/kg body weight of the extract and 5 mg/kg body weight of Lead II oxide, Group D₂ received 5 mg/kg body weight of Lead II oxide and 200 mg/kg body weight of the extract, Group E received 500 mg/kg body weight of Vitamin E only and Group F received 500 mg/kg body weight of vitamin E and 5 mg/kg body weight of Lead II oxide respectively.

Animal sacrifice

The animals were sacrificed by cervical dislocation 12 hours after the last administration and the testis was excised following the abdominal incision, fixed in 10% formal saline for histological analysis.

Analytical Procedure

Histological analysis

Testes were carefully dissected out following abdominal incision and fixed in 10% formol-saline and processed routinely for paraffin embedding. 5 μ sections were obtained with rotary microtome and processed for Hematoxylin and Eosin Stalin (H/E) according to the method described by Akpantah et al. [13] and Sections were observed.

Result and Discussion

Histological examination of the testes of rats treated with Lead II oxide revealed degeneration in spermatogonia cells lining the seminiferous tubules (Figure 1), associated with incomplete

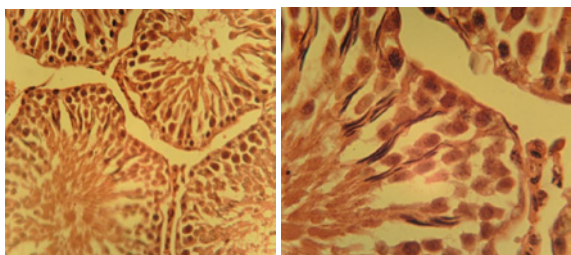


Figure 1: H and E staining of transverse section of rat testis of Group C (lead only). Showing abnormal widening of interstitial spaces (IS) with degeneration of interstitial cells (IC). Increased Intracellular spaces in seminiferous tubule (ST) were observed (Magnifications C₁: X400 and C₂: X1000).

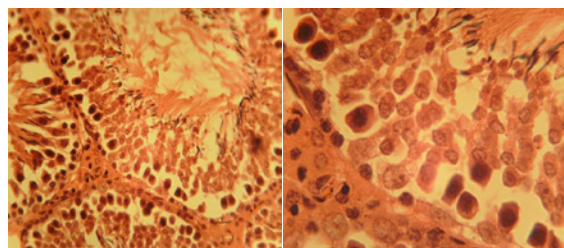


Figure 2: H and E staining of transverse section of rat testis of Group A (control) shows seminiferous tubule (ST) containing different types of germ cells; spermatogonia type A (S_A) lying on the basement membrane (BM) beneath which is the myofibroblast (MF), spermatogonia type B (S_B), spermatocytes, spermatids spermatozoa (SP) and somatic sertoli cells (St). The interstitial tissues found between seminiferous tubules contain interstitial cells; leydig cells (LC) and myoid cells (MC). (Magnification A₁: X400 and A₂: X1000).

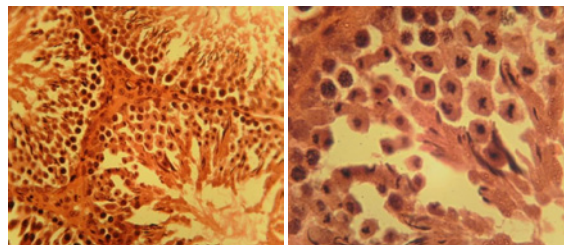


Figure 3: H and E staining of transverse section of rat testis of Group B (extract only). Showing Interstitial cells (IC) of the interstitial spaces (IS) and seminiferous tubules (ST). (Magnifications B₁: X400 and B₂: X1000).

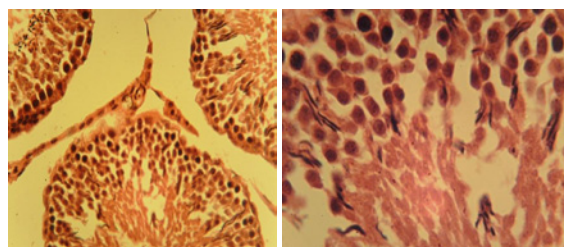


Figure 4: H and E Staining of transverse section of rat testis of Group D₂, shows an increased interstitial space with reduced interstitial cells (IC), seminiferous tubule (ST) not much affected. (Magnification D_{2A}: X400 and D_{2B}: X1000).

spermatogenesis when compare with the positive control group (Figure 2) and the group that received extract only (Figure 3). Photomicrograph in figures 2 and 3 depict normal histo-architecture of the testes which expresses Seminiferous Tubule (ST) containing different types of germ cells; Spermatogonia Type A (SA) lying on the Basement Membrane (BM) beneath which is the Myofibroblast (MF), Spermatogonia type B (SB), spermatocytes, Spermatids Spermatozoa (SP) And Somatic Sertoli Cells (St). The interstitial tissues found between seminiferous tubules contain interstitial cells; Leydig Cells (LC) and Myoid Cells (MC). Slight degeneration of germ cells lining seminiferous tubules with desquamation of germ cells and the tubular lumen were filled with degenerated germ cells, interstitial spaces were abnormally widening with degeneration of leydig cells (Figure 3). Improvement in the histopathological picture was noticed in examined sections from rats treated with combined Lead II oxide and *Garcinia kola* as well as rats treated with Lead II oxide and Vitamin E as the examined sections revealed apparent normal seminiferous tubules (Figures 4

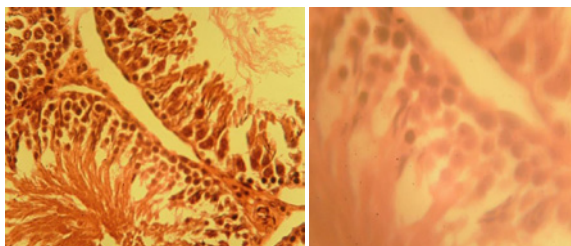


Figure 5: H and E staining of transverse section of rat testis of Group E. Seminiferous tubule (ST) integrity maintained with slight increase of interstitial spaces (IS) with interstitial cells. (Magnification E₁: X400 and E₂: X1000).

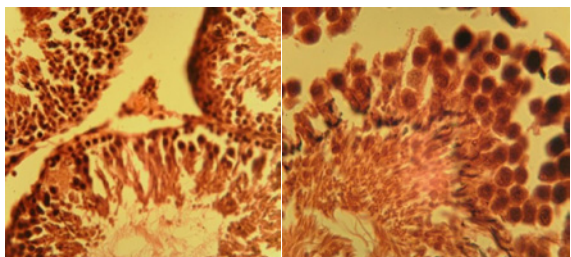


Figure 6: H and E staining of transverse section of rat testis of Group D₁. Seminiferous tubule (ST) and increased interstitial spaces (IS) with reduced Leydig concentration compared to control. (Magnification D_{1A}: X400 and D_{1B}: X1000).

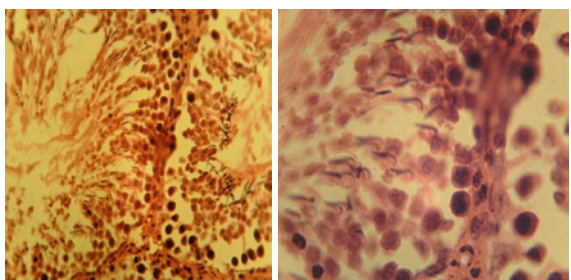


Figure 7: H and E staining of transverse section of rat testis in Group F. Structural integrity of seminiferous tubule and interstitial cells maintained. (Magnification F₁: X400 and F₂: X1000).

and 5) and interstitial spaces occupied by the Leydig cells. Histological observations of the Group 1 revealed normal architecture (Figure 1) of the seminiferous tubule with the germinal epithelium at different stage of development. Spermatogonia lying on the basement membrane (BM) and beneath it are the Myofibroblast (MF), spermatocytes, Spermatid Spermatozoa (SP) and Somatic Sertoli Cells (St). The interstitial tissues found between seminiferous tubules contain interstitial cells; Leydig Cells (LC) and myoid cells.

Histological integrity of the rats in Group B and Group E was maintained (Figures 3 and 5), showing normal histological characteristic of the seminiferous tubule and the interstitial space of the testis when compare with the rats that was treated with Lead II oxide (Group C) which show a marked increased in the interstitial spaces with degeneration of the Leydig cell or interstitial cells (Figure 1). The group that was treated with 200 mg/kg of the extract and Lead II oxide show relative improvement in the germinal epithelium, spermatogonia, spermatid and spermatocytes contain in the seminiferous tubule (Figure 4) when compare with the group treated with 100 mg/kg of the extract and Lead II oxide as shown in figure 6. Structural integrity

of seminiferous tubule and interstitial cells maintained in Group F treated with both Lead II oxide and Vitamin E as revealed by the photomicrograph in figure 7. Administration of *Garcinia kola* seed extract caused an increase in testosterone production in Sprague-Dawley rats which is thought to be due to its antioxidant properties [13]. Also, Adesanya et al. [14] confirmed the spermatogenic and tissue enhancing effect of *Garcinia kola* extract in male Wistar rats. The antioxidant property of *Garcinia kola* is attributed to its very high content of ascorbic acid [7]. Its mineral content includes potassium, calcium, magnesium, nitrogen and phosphorous [7].

The present study demonstrated that administration of *Garcinia kola* attenuate the histological alteration in the testis caused by Lead II oxide in adult wistar rats.

Improvement in the histopathological picture was noticed in examined sections from rats treated with combined Lead II oxide and *Garcinia kola* as well as rats treated with Lead II oxide and Vitamin E as the examined sections revealed apparent normal seminiferous tubules and the presence of Leydig cells in the interstitial spaces. Administration of Lead II oxide in group C shows a significant decrease in the activities of steroidogenic cell of the interstitial spaces. Interstitial cells show a marked degeneration as the interstitial spaces were abnormally widening in the group treated with Lead II oxide. Testicular integrity was maintained in the Group treated with *Garcinia kola* and Vitamin E; normal component of the seminiferous tubule and the interstitial spaces were maintained showing the Leydig cells this is in accordance with of work [14].

Lead II oxide treated rats show significant decrease in the steroidogenic cell; Steroidogenic cell respond to the gonadotrophins which control the secretion of testosterone. Gonadotrophins act, synergistically to augment serum endogenous testosterone levels by short feedback loop but can bring down its level by negative feedback mechanism. Lead II oxide was seen to induce testicular damage in rats; this might be resulted from the ability of Lead ions to generate reactive oxygen species capable of soft tissue break-down according to [16]. Lead had been reported to induced oxidative stress in blood and other soft tissue [17-19]. Disruption of pro-oxidant/antioxidant balance might lead to the tissue injury. It was also reported that Lead increased the level of lipid peroxidation an indication of tissue damage. Sperm plasma membrane has a high content of polyunsaturated fatty acids which is easily susceptible to lipid peroxidation caused by oxidative stress [20]. Excessive ROS production that exceeds critical levels can overwhelm all antioxidants defense strategies of spermatozoa and seminal plasma causing oxidative stress that damages the biological membranes in the testes. This in turn may cause the degeneration of the spermatogenic and Leydig cells, which disrupts spermatogenesis and reduces sperm counts [21].

Garcinia kola and Vitamin E show slight improvement in the steroidogenic cell in testes damaged with Lead II oxide when compare with Group C that received Lead II oxide only. This was in agreement with the work carried out by Braide et al. [22] who reported a significant reduction in serum testosterone of male albino rats administered with crude alkaloid extract of *Garcinia kola* seed and oppose the work of Akpantah et al. [13], who recorded no histological difference in the testes of wistar rats.

Conclusions

Garcinia Kola and Vitamin E had been seen to demonstrate hepato-protective action against the oxygen free radical generated by

the presence of Lead ions by maintaining the histological integrity of the testis of wistar rats.

Acknowledgement

We Appreciate the Technicality and Support of Workers in Animal Holding Facility, Anatomy, Biochemistry and Physiology Laboratory, College of Health Sciences, Bingham University, Karu, Nigeria.

References

1. Sastre J, Pallardo FV, Garcia de la Asuncion J, Vina J (2000) Mitochondria, oxidative stress and aging. *Free Rad Res* 32: 189-198.
2. Adhikari N, Sinha N, Narayan R, Saxena DK (2001) Lead Induced cell death in testes of young rats. *J Appl Toxicol* 21: 275-277.
3. Batra N, Nehru B, Bansal MP (2001) Influence of Lead and Zinc on rat male reproduction at biochemical and histopathological levels. *J Appl Toxicol* 21: 507-512.
4. Boscolo P, Carmignani M, Sacchettoni-Logroschino G, Rannelletti FO, Artese L, et al. (1988) Ultrastructure of the testis in the rats with blood hypertension induced by long term lead exposure. *Toxicol Lett* 41: 129-137.
5. Ramadan A, Harraz FM, El-Mougny SA (1994) Anti-inflammatory, analgesic and antipyretic effects of the fruit pulp of *Adansonia digitata*. *Fitoterapia* 65: 418-422.
6. Knight JA (2000) Review: free radicals, antioxidants and immune system. *Ann Clin Lab Sci* 30: 145-158.
7. Okwu DE, Ekeke O (2005) Phytochemical screening and mineral composition of chewing sticks in Eastern Nigeria. *Global J Pure Appl Sci* 9: 235-238.
8. Hussain RA, Owegby AG, Parimoo P, Waterman PG (1982) Kolanone, a novel polyisoprenylated benzophenone with antimicrobial properties from the fruit of *Garcinia kola*. *Planta Med* 44: 78-81.
9. Ebanu RU, Madunagu BE, Ekpe ED, Otung IN (1991) Microbiological exploitation of cardiac glycosides and alkaloids from *Garcinia Kola*, *Borreria Ocyroides*, *kolanitida* and *citrus aurantifolia*. *J Appl Bacteriol* 71: 398-401.
10. Iwu M (1993) *Handbook of African Medicinal Plants*. CRC press. Florida, USA.
11. Akintonwa A, Essien AR (1990) Protective effects of *Garcinia kola* seed extract against paracetamol-induced hepatotoxicity in rats. *J Ethnopharmacol* 29: 207-211.
12. Mahendran P, Vanisree AJ, Shyamala Devi CS (2002) The antiulcer activity of *Garcinia cambogia* extract against indomethacin-induced gastric ulcer in rats. *Phytother Res* 16: 80-83.
13. Akpantah AO, Oremosu AA, Ajala MO, Noronha CC, Okanlawon AO (2003) The effect of crude extract of *Garcinia Kola* seed on the histology and hormonal milieu of male Sprague-Dawley rats' reproductive organs *Niger J Health Biomed Sci* 2: 40-46.
14. Adesanya OA, Oluyemi KA, Ofusori DA, Omotuyi IO, Okwuonu CU, et al. (2007) Micromorphometric and stereological effects of ethanolic extracts of *Garcinia cambogia* seeds on the testes and Epididymides of adult Wistar Rats: *The Internet Journal of Alternative Medicines* 5.
15. Braide VB (1989) Antispasmodic extracts from seeds of *Garcinia kola*. *Fitoterapia* :123.
16. Gurer H, Ercal N (2000) Can antioxidant be beneficial in the treatment of lead poisoning? *Free Radic Biol Med* 29: 927-945.
17. Waters M, Stasiewicz S, Merrick BA, Tomer K, Bushel P, et al. (2008) CEBS-*Chemical Effects in Biological Systems: a public data repository integrating study design and toxicity data with microarray and proteomics data*. *Nucleic Acids Res* 36: 892-900.
18. Auman JT, Chou J, Gerrish K, Huang Q, Jayadev S, et al. (2007) Identification of genes implicated in methapyrilene-induced hepatotoxicity by comparing differential gene expression in target and nontarget tissue. *Environ Health Perspect* 115: 572-578.
19. Pande M, Flora SJ (2002) Lead induced oxidative damage and its response to combined administration of alpha-lipoic acid and succimers in rats. *Toxicology* 177: 187-196.
20. Agarwal A, Prbakaran SA, Said TM (2005) Prevention of oxidative stress injury to sperm. *J Androl* 26: 654-660.
21. Latchoumycandane C, Chitra KC, Mathur PP (2002) The effect of methoxychlor on the epididymal antioxidant system of adult rats. *Reprod Toxicol* 16: 161-172
22. Braide VB, Agube CA, Essien GE, Udoh FV (2003) Effect of *Garcinia kola* seed alkaloid extract on levels of gonadal hormones and pituitary gonadotrophins in rat serum. *Niger J Physiol Sci* 18: 59-64.