

See discussions, stats, and author profiles for this publication at: <https://www.researchgate.net/publication/360779588>

Ibuprofen-induced Gastric Ulcer in Wistar rats: Evaluating the Impact of Fermented Ripe and Unripe Carica papaya compared to Omeprazole

Article in *International Journal of Pharmaceutical Sciences Review and Research* · April 2022

DOI: 10.47583/ijpsrr.2022.v73i02.017

CITATIONS

0

READS

118

6 authors, including:



Sunday Elijah

PAMO University of Medical Sciences

6 PUBLICATIONS 0 CITATIONS

[SEE PROFILE](#)



Mirabel Amadi

Ignatius Ajuru University of Education

10 PUBLICATIONS 0 CITATIONS

[SEE PROFILE](#)



Onyeleonu Ijeoma

PAMO UNIVERSITY OF MEDICAL SCIENCES

7 PUBLICATIONS 32 CITATIONS

[SEE PROFILE](#)



Joseph Enya

PAMO

14 PUBLICATIONS 50 CITATIONS

[SEE PROFILE](#)

Some of the authors of this publication are also working on these related projects:



Garcinia koli (GKE) as Potential Anti-Inflammatory Treatments for Novel COVID-19 (nCoV-19) [View project](#)

Research Article



Ibuprofen-induced Gastric Ulcer in Wistar rats: Evaluating the Impact of Fermented Ripe and Unripe *Carica papaya* compared to Omeprazole

Helen Bassey Akpan*, Sunday Okon Elijah, Michael Anozie Amadi, Ijeoma Onyeleonu, Joseph Igbo Enya*, Blessing Tamunoibelega Fubara

Department of Anatomy, Faculty of Basic Medical Sciences, PAMO University of Medical Science, PUMS, Port Harcourt, Rivers State, Nigeria.

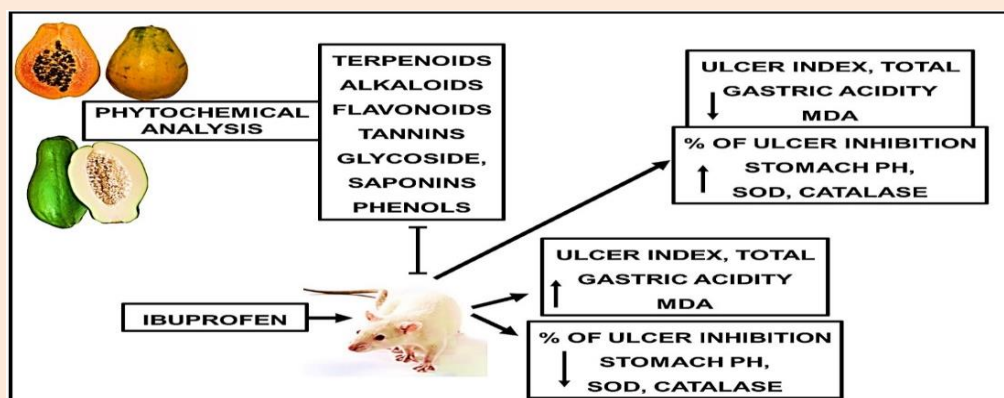
*Corresponding author's E-mail: hbakpan@pums.edu.ng

Received: 02-01-2022; Revised: 24-03-2022; Accepted: 02-04-2022; Published on: 15-04-2022.

ABSTRACT

Gastric ulcers are common menace of the upper gastrointestinal tract (GIT) disorders. Despite the high healing rate of several synthetic drugs, their therapy does not provide a comprehensive protective/curative impact against this GIT disorder. We compared the effects of fermented ripe and unripe *Carica papaya* (*C.papaya*) extracts and omeprazole on ibuprofen-induced gastric ulcer in Wistar rat models. Phytochemical assessment was done on fermented extract, followed by a pilot study to determine the exact dose and effect on the rats. Adult Wistar rats (n=35) employed in this present study, were randomly assigned into 7 groups (G1-G7, n=5) and treated orally as follows: G1-Control; G2-Ibuprofen; G3-Ibuprofen+fermented unripe *C.papaya*; G4-Ibuprofen+fermented ripe *C.papaya*; G5-Fermented ripe *C.papaya*+Ibuprofen; G6-Fermented unripe *C.papaya*+Ibuprofen; G7-Ibuprofen+omeprazole. Phytochemical analysis revealed that *C. papaya* extracts contain terpenoids, alkaloids, flavonoids, tannins, glycosides, saponins, and phenols of which fermented unripe *C. papaya* contains higher quantities compared to fermented ripe. Ibuprofen treatment significantly induced weight loss, increased ulcer index, total gastric acidity and lead to a non-significant reduction in stomach weight, % of ulcer inhibition and stomach pH. It significantly reduced SOD, CATALASE and increased MDA levels of expression. Histoarchitecture revealed erosion in the epithelial lining in the mucosae, resulting from mucosa cell necrosis and congestion. However, there were substantial ameliorative improvements in the evaluated parameters, following fermented unripe *C.papaya* and fermented ripe *C.papaya* therapy in all groups. In conclusion, fermented ripe and unripe *C. papaya* may have both an ameliorative and protective effect on ibuprofen induced gastric ulcers as compared to omeprazole.

Graphical abstract



Keywords: Toxicity; Gastrointestinal tract; *C. papaya* extract; gastric ulcer; protective effects.

QUICK RESPONSE CODE →

DOI:

10.47583/ijpsrr.2022.v73i02.017



DOI link: <http://dx.doi.org/10.47583/ijpsrr.2022.v73i02.017>

INTRODUCTION

One of the most frequent diseases that afflicts people is peptic ulcer. Peptic ulcer is an acid-induced digestive tract lesion characterized by denuded mucosa with the defect extending into the

submucosa or muscularis propria. It commonly occurs in the lining of the stomach (gastric ulcer) or proximal duodenum (duodenal ulcer) as sores.¹ *H. pylori* infection, stress, diet, alcohol and cigarette intake, use of nonsteroidal anti-inflammatory medicines (NSAIDs) etc are all risk factors for developing a peptic ulcer.² The modern therapy for treating ulcers is conventional medications such as histamine H₂-receptor antagonists (H₂RAs) (e.g., cimetidine and ranitidine) and proton pump inhibitors (e.g., omeprazole), but these drugs have some side effects.³ Numerous studies have shown that plants, through various methods, can effectively cure ulcers in humans and animals.⁴ Plants' efficacy has also been shown



in studies to be comparable to or even superior to that of pharmaceuticals, with fewer side effects.^{4,5}

Plants have been used as a source of antibiotics, anti-inflammatory, antineoplastics, analgesics, cardioprotective, and other medications for over 5000 years.^{6,7} Humans have been employing natural substances to fight infections and other ailments in the recent past.⁸ Plants' bioactive chemicals, which humans rely on, are the most powerful and promising ingredients.⁹ Bioactive chemicals are substances with therapeutic potential for lowering pro-inflammatory states, oxidative stress, and metabolic diseases while increasing calorie intake.¹⁰ These bioactive substances are found in modest amounts in foods, primarily fruits, vegetables, and whole grains, and give health advantages in addition to basic nutritional value.¹¹ Their impact on health is still being studied. *Carica papaya* (*C. papaya*) is an example of a fruit that contains these bioactive properties such as antioxidant, antibiotics and anti-inflammatory.

Many physiologically active compounds are found in *C. papaya*, including carica papain lipase or caplahydroloses, which is a "naturally immobilized" biocatalyst, and the two major components chymopapain and papain, which are commonly used for digestion disorders and gastrointestinal disturbances.¹² Phytochemical analysis of all portions of *C. papaya* revealed the presence of alkaloids, cardiac glycosides, anthroquinones, saponins, tannins, flavonoids, and carbohydrates, according to reports.¹³⁻¹⁵ Alkaloids (isolated or synthetically produced) from plant are employed as antimicrobial agents; in fact, *C. papaya* fruit and seed have been found to be effective against malaria, as alkaloid contains quinine, which is an anti-malaria.¹² Flavonoids are phenolic chemicals that have been shown to have antiviral, antibacterial, and spasmolytic effects.¹⁶ Tannins have antibacterial properties because of their ability to combine with proteins to generate stable water-soluble chemicals, killing bacteria by destroying their cell membrane directly.¹⁷

Traditional medicine practitioners use *C. papaya* to treat a variety of maladies, including but not limited to sore throats, asthma, sickle cell anemia, wounds, boils, pain, tonsillitis, jaundice, cancer, stomach disorders, diarrhoea, skin diseases, male contraceptives, and home treatments for colds.¹⁸ Unripe *C. papaya* fruit possesses anti-sickling, laxative, abortifacient, and diuretic qualities, according to reports.¹⁹ The consumption of the plant's unripe fruit extract has been connected to an anti-ulcer effect.^{20,21} Although Owoyele and cohort conducted a study²¹ to see if the practice of traditional medicine practitioners utilizing fermented unripe *C. papaya* fruit to reduce ulcer index in indomethacin induced gastric ulcer is useful. There hasn't been much research on whether fermented ripe *C. papaya* is as effective as unripe *C. papaya*. As a result, this experiment will use ibuprofen to induce stomach ulcers in adult Wistar rat models, with the goal to compare the effects of fermented ripe and fermented unripe *C. papaya*, using omeprazole as a standard control.

MATERIALS AND METHODS

Ethical approval and Animals Procurements for Study

All procedures on animal handling were strictly carried out, according to the guidelines of the Institutional Animal Care and Use Committee (IACUC) as approved by the PUMS Animal Research Ethics Committee (PUMS-AREC), PUMS, Port Harcourt, Rivers State, Nigeria.

The adult Wistar rats of both sexes weighting an average of 160±10g were acquired from the animal holding, Pamo University of Medical Sciences (PUMS) animal holdings facility, Port Harcourt, Rivers State. Rats were allowed to acclimatize to their new environment for 2 weeks in various standard polypropylene cages, under standard laboratory conditions at the PUMS animal holdings facility, where they had free access to rat chow and water *ad libitum*.

Animal grouping and treatments

Adult Wistar rats (n=35) employed in this present study, were randomly assigned into 7 groups (G1-Control; G2-Ibuprofen; G3-Ibuprofen+fermented unripe *C. papaya*; G4-Ibuprofen+fermented ripe *C. papaya*; G5-Fermented ripe *C. papaya*+Ibuprofen; G6-Fermented unripe *C. papaya*+Ibuprofen; G7-Ibuprofen+omeprazole. n=5 each) and treated orally as follows: G1 (1ml of distilled water. G2, G3, G4 and G7 were administered with a single dose of ibuprofen-IBU (400 mg/kg B.W). After 6 hours of ulcer induction, G3, 4 and 7 further received fermented unripe (FUP), fermented ripe (FRP) *C. papaya* extracts (0.75ml extract + 0.25ml distilled water based on pilot study) and omeprazole (OME; 20mg/kg B.W.) respectively. This treatment continued for fourteen days. G5 and G6 received FRP and FUP extracts respectively for twelve days at first. 30 minutes after the last extract administration on the twelfth day, animals in both groups were further administered ibuprofen (400mg/kg B.W) once daily from day 12 through day 14. In addition, Before the commencement and after the conclusion of this study, rats were weighed using a weighing scale (Atom electronic compact scale), to determine if the treatment affected their body weight.

Procurement and authentication of *Carica Papaya*

Ibuprofen (Ebu-400/400mg) and Omeprazole (Ome/20mg) were purchased from Wilson pharmacy, #682 Ikwerre road, Rumuokoro, Port-Harcourt, River State, Nigeria.

Fresh *C. papaya* fruit (both unripe and ripe) were obtained from the local oyigbo market at oyigbo, LGA of River State. They were identified and authenticated in the Department of Plant Science and Biotechnology, University of Port Harcourt, Rivers State, with authentication number; UPH/PSB/2021/A15a and UPH/PSB/2021/A15b allocated to the ripe and unripe *Carica papaya* fruit respectively.

Stomach ulcer induction

With reference to Goorani, et al.,⁴⁵ method, freshly prepared ibuprofen (400mg/kg) was measured and



dissolved in distilled water. Wistar rats were fasted for 24 hours prior to oral administration of ibuprofen (400mg/kg), afterwards, allowed for 6 hours.

Carica Papaya fermentation and treatment procedure

We carried out *C. papaya* fermentation with slight modification, referencing the methods of Ezike, *et al.*, and Owoyele and cohort.^{20,21} *C. papaya* fruits were thoroughly washed with running tap water. The entire unripe *C. papaya* fruits was weighed using a weighing scale and grated using a plastic grater (shredder). The grated fruits were then fermented for four days in a fermenting jar holding two litres of water.²¹ To obtain the juice (fermented), the grated fermented unripe *C. papaya* fruits were sieved using chiffon cloth (sieve) and the juice extract placed in a plastic bottle and allowed to settle in a refrigerator for a day. The juice extract was then decanted to collect the sediments. The sediments were then subjected to phytochemical analysis and refrigerated until therapy.²⁰ The ripe *C. papaya* fruits were also subjected to this protocol however 2.2 litres of water were used.

Prior to this work, we introduced a pilot study to determine the appropriate dosage for the study. In a brief, Wistar rats were subjected to 25%, 50%, 75%, and 100% oral administration of fermented extract. General observations were made on the eating habit, fecal matter, social activity and agility, and as well, histological analysis and biochemical assays were carried out in order to select the most effective dose.

Sacrifice and Tissue Processing

Rats for histology were euthanized using chloroform vapor and then subjected to transcardial perfusion using 50 ml of 0.1 M PBS (pH 7.4) and then followed by 500 ml of 10% buffered formalin. Using surgical blade, scissor and scalpel, the stomach of the animals was dissected out and an incision was made at the greater curvature in order to collect gastric contents and to observe gastric mucosa for the presence of gastric ulceration. The stomach was then rinsed in PBS, and then post-fixed in 10% buffered formalin solution and taken for histological (H&E) tissue processing. Rats processed for biochemical study were not subjected to transcardial perfusion. The stomach was excised, rinsed in PBS, placed in PBS and then preserved in a cooling medium, after which sections of the stomach were homogenized for biochemical assay.

Ulcer Score and Index

Ulceration was confirmed by using a hand-held lens (x10) and the ulcer score was determined using the arbitrary scale.²¹ **Table 1** reveal the gross scoring system for gastric ulcer. The ulcer index was calculated as the mean of ulcer score;

$$\text{Ulcer index (UI)} = \frac{\text{Total of ulcer score}}{\text{Number of animals ulcerated}}$$

Whereas the ulcer inhibition described by Main & Whittle,²² used in Mekonnen, *et al.*,²³ was calculated as;

$$\text{Inhibition (\%)} = \frac{\text{UI}_{\text{MODEL CONTROL}} - \text{UI}_{\text{TREATED}}}{\text{UI}_{\text{MODEL CONTROL}}} \times 100 \text{ acidity (mEq/L)}$$

Table 1: Gross scoring system for gastric ulcer

Code/score	Meaning
0	No Visible Lesion
0.5	Hyperaemia
1	One or Two Slight Lesions
2	Severe Lesions
3	Very Severe Lesions
4	Mucosa Full of Many Lesions

Determination of Gastric Acidity

Samples of gastric contents from each rat were collected and centrifuged (2000 rpm) for 10 minutes, after which 5 ml of the supernatant (PBS was added to make it up) was analysed for hydrogen ion concentration by titration against 0.1 M NaOH to a pH of 7.0 using phenolphthalein as an indicator,²¹ Acidity was calculated by using the formula below;

$$\text{Acidity} = \text{Volume of NaOH} \times \text{Molarity of NaOH} \times \text{mEq/L}/100\text{g}$$

pH determination (Potentiometric Analysis)

The pH of the stomach contents was calculated using the formula stated below;

$$\text{MaVa} = \text{MbVb}$$

$$\text{Therefore; Ma} = \frac{\text{Mb} \times \text{Vb}}{\text{Va}}$$

Where, M (a)/ (b)= molarity of acid/ base

$$\text{V (a)/ (b)} = \text{volume of acid / base}$$

Therefore; pH of sample = -log (molarity of acid)

Data analysis

The data obtained were tested for analysis of variance (ANOVA) with Tukey's multiple comparisons test, analyzed using GraphPad Prism® software (Version 8.1). Statistical significance was set at p<0.05.

RESULTS

FUP and FRP Phytochemical Analysis

Table 2: Phytochemical analysis of FRP and FUP

PHYTOCHEMICALS	FRP	FUP
Alkaloids	+	+
Terpenoids	+	+++
Saponins	+	++
Flavonoids	+	+++
Tannins	+	+++
Glycosides	+++	+
Phenols	++	+++

NOTE: FRP (fermented ripe *C. papaya*); FUP (fermented unripe *C. papaya*)



Phytochemicals are non-nutrient bioactive plant chemicals found in fruits, vegetables, grains, and other plant foods that have been related to a lower risk of major chronic diseases. The analysis done in duplicate revealed the following in *table 2*.

IBU-induced Body and Stomach Weight Loss was Improved more by FUP and FRP extracts Treatment when compared to OMA treatment

Severe loss of body and organ (such as stomach) weight can be a determining factor in assessing the phases and severity of different disease states. After 2 weeks (14 days) of acclimatization period, the present study took into consideration the initial weight of Wistar rats in each group until the last day of the experiment where the final body weight was taken, in-order to ascertain the weight gain overtime. As seen in *fig 1a-b*, there was no body weight gain, but rather an observed deterioration of stomach weight among rats that were given IBU (400mg/kg) when compared to other experimental groups. However, protective and therapeutic intervention with FUP and FRP extracts following IBU treatment, progressively improved the food consumption rate of Wistar rats which correlates to the slight increase of body weight gain and stomach weight as well. Comparing the positive effects of FUP and FRP extracts with OME, there was no significant difference ($p < 0.05$) in body weight except G6 treated Wistar rats, of which significantly increased when compared with OME (G7) treated rats. Quite similar, the stomach weight progressive improvement across intervention groups revealed no statistically significant difference ($p < 0.05$).

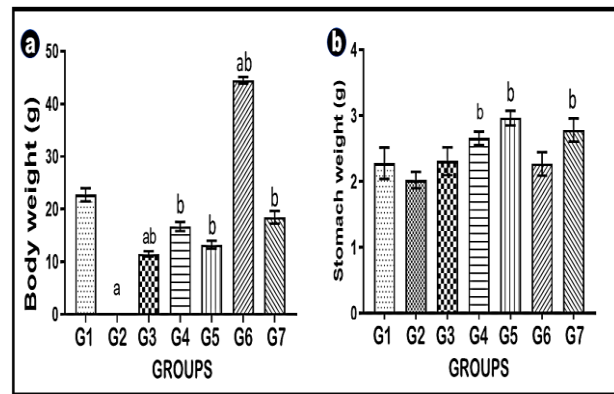


Figure 1a-b: Wistar rats body weight gain and stomach weight. (a) body weight; (b) Stomach weight. G1-control; G2-IBU; G3-IBU+FUP; G4-IBU+FRP; G5-Pretreated FRP+IBU; G6-Pretreated FUP+IBU; G7-IBU+OME. Note: IBU (Ibuprofen), FUP (fermented unripe *C. papaya*), FRP (fermented ripe *C. papaya*) and OME (Omeprazole). * $p < 0.05$ and ^b $p < 0.05$ denote statistically significant when compared with G1 and G2 respectively.

FUP and FRP extracts influence Ulcer Parameters more when compared to OMA treatment

The increase in ulcer index (*see fig. 2a*) and no ulcer inhibition (*see fig. 2d*) following IBU treatment (G2) clearly explains the compromise in the integrity of the mucosal protection, correlating the damages caused by IBU (400mg/kg bw) administration to induce stomach ulcer in G2 Wistar rats. Also, a statistically significant increase ($p < 0.05$) in total gastric acidity (*see fig. 2b*) was observed while the stomach pH (*see fig. 2c*) revealed a non-statistically significant reduction following IBU treatment. These changes were ameliorated greatly following FUP and FRP extracts protective and therapeutic intervention. Generally, comparing the positive effects of FUP and FRP extracts with OME across probed parameters (*see fig. 2a-d*), there was no statistically significant difference ($p < 0.05$).

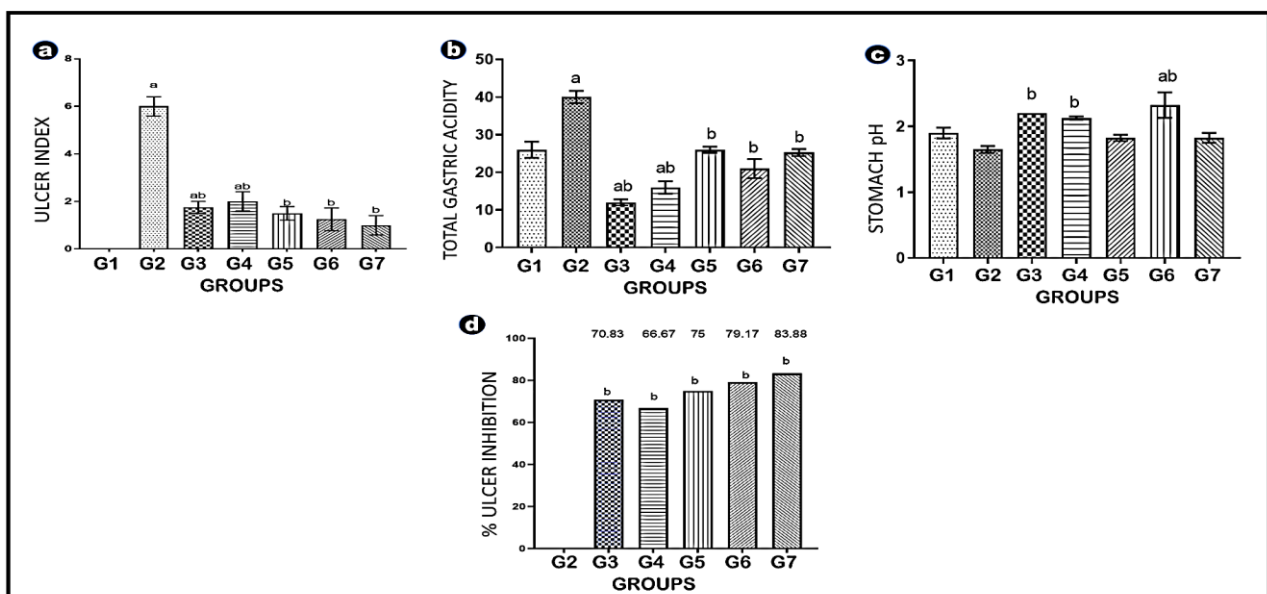


Figure 2a-d: Wistar rats Ulcer Parameters. (a) Ulcer Index; (b) Total Gastric Acidity; (c) Stomach pH; (d) % Ulcer Inhibition. G1-control; G2-IBU; G3-IBU+FUP; G4-IBU+FRP; G5-Pretreated FRP+IBU; G6-Pretreated FUP+IBU; G7-IBU+OME. Note: IBU (Ibuprofen), FUP (fermented unripe *C. papaya*), FRP (fermented ripe *C. papaya*) and OME (Omeprazole). * $p < 0.05$ and ^b $p < 0.05$ denote statistically significant when compared with G1 and G2 respectively.

FUP and FRP Improves Anti-Oxidative Mechanism and Downregulates IBU-induced Lipid Peroxidation of the stomach

The generation of reactive oxygen species (ROS) and oxidative stress damage is a crucial step in the pathogenesis of gastric ulcer. Oxidative stress is a state that has been shown to change a variety of physiological reactions, and it has a role in both psychological and pathological onset of stomach ulcer. Results in this present study show that IBU-intake significantly encouraged oxidative stress in the stomach of rats when compared to the stomach of rats in other groups, resulting in the upsurge level of MDA (see fig. 3c). However, IBU-induced lipid peroxidation of the stomach of treated rats, reveals a significant decrease of MDA expression level following FUP and FRP extracts protective and therapeutic intervention.

Further, we measured stomach lysate levels of antioxidant enzymes, SOD and Catalase (see fig. 3 a and b

respectively), to enable us examine the effectiveness of FUP and FRP extracts. SOD and Catalase have been shown to catalyse the elimination of free radicals, lowering their reactive potentials and thereby preventing oxidative cytotoxicity. Results in this present study shows that IBU-intake significantly discouraged the activities of antioxidant enzymes in the stomach of rats when compared to the stomach of rats in other groups, resulting in the decline level of SOD and Catalase. However, protective and therapeutic intervention with FUP and FRP extracts following IBU treatment, progressively improved the activities of antioxidant enzymes in the stomach of rats. However, comparing the positive effects of FUP and FRP extracts with OME on stomach lipid peroxidation and antioxidant activities across probed parameters (see fig. 3a-c), there was no statistically significant difference ($p < 0.05$).

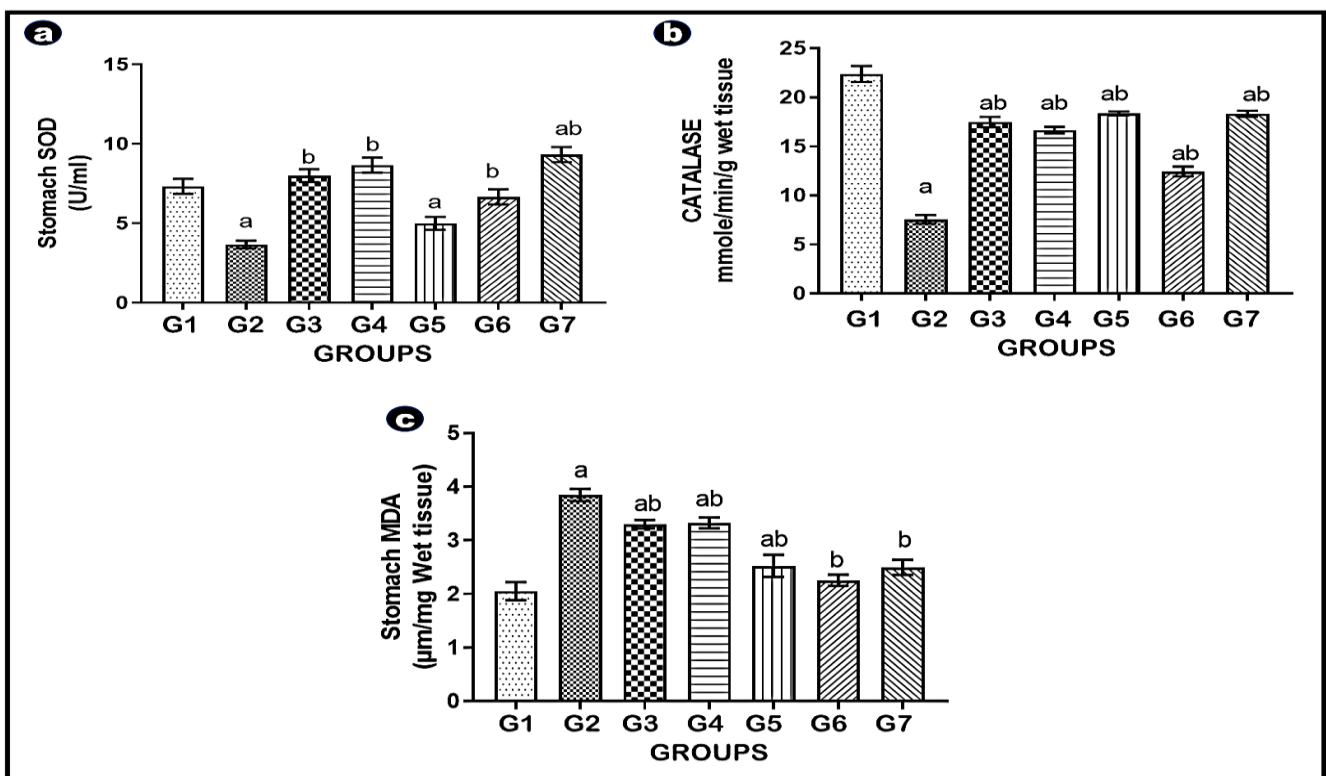


Figure 3a-c: Stomach Lipid Peroxidation and Antioxidant Expression. (a) SOD; (b) CATALASE; (c) MDA. G1-control; G2-IBU; G3-IBU+FUP; G4-IBU+FRP; G5-Pretreated FRP+IBU; G6-Pretreated FUP+IBU; G7-IBU+OME. Note: IBU (Ibuprofen), FUP (fermented unripe *C. papaya*), FRP (fermented ripe *C. papaya*) and OME (Omeprazole). ^a $p < 0.05$ and ^b $p < 0.05$ denote statistically significant when compared with G1 and G2 respectively.

FUP and FRP Normalized the cytoarchitectural alteration of IBU-induced stomach ulcer

The anatomical presentation of the histological properties of the stomach in this present study was demonstrated using the H&E staining technique. The general histoarchitecture of the stomach of control (CON) rats showed that, the mucosa (M) of the stomach has the characteristic villous with glandular crypts between the villi (V) extending down to the muscularis mucosae (MM).

At higher magnification, Ibuprofen treated rats exhibited gaps in the mucosae (red arrow), resulting from mucosa cell necrosis and congestion (red circle) and destruction of the lamina propria. Also present were severe erosion with strong infiltration of inflammatory cells and haemorrhage at the submucosa. However, there was substantial ameliorative improvement following fermented ripe and unripe *C. papaya* treatment in both protective and therapeutic interventions (see fig. 4).

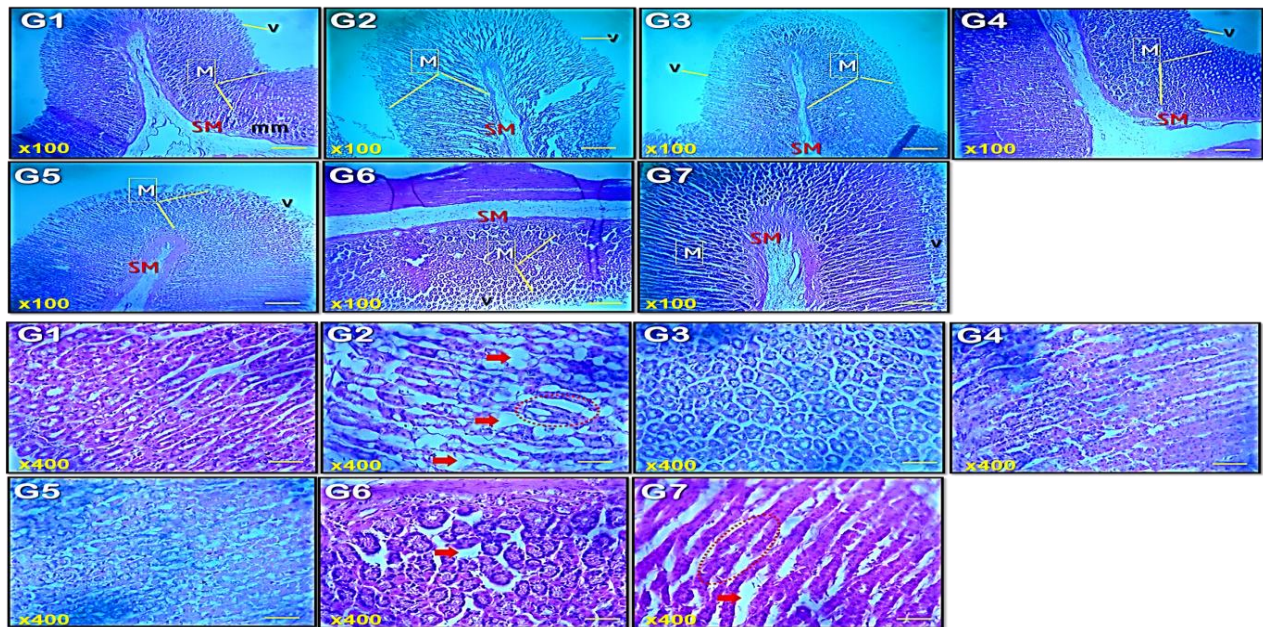


Figure 4: Stomach Histoarchitecture. G1-control; G2-IBU; G3-IBU+FUP; G4-IBU+FRP; G5-Pretreated FRP+IBU; G6-Pretreated FUP+IBU; G7-IBU+OME. Note: IBU (Ibuprofen), FUP (fermented unripe *C. papaya*), FRP (fermented ripe *C. papaya*) and OME (Omeprazole). Mucosa (M): Villi (V); Muscularis mucosae (MM); Submucosa (SM). (H&E x100 and x400).

DISCUSSION

It is fascinating to ponder why some plants are used to treat different ailments. *C. papaya* is a useful plant for traditional medical practitioners, used to treat a variety of ailments such as warts, cancer, burns, and jaundice, among others.^{21,24} Previous research has looked into a variety of phytochemical, anti-oxidant, and Nutra-pharmaceutical qualities of the fruit, as well as the plant itself, based on ethnopharmacological knowledge, in order to better understand its uses.²¹ However, we specifically considered *C. papaya* phytochemical properties after fermentation protocols.

C. papaya fruit Phytochemical findings

From this research, the phytochemical results showed that both the fermented unripe (FUP) and ripe (FRP) *C. papaya* possessed phytochemicals that have shown some therapeutic prospects in managing several ailments. In their fermented state, the results of phytonutrients obtained in the present study were comparable with results reported earlier by other authors including Dada *et al.*; Prabhu *et al.*, and Oluchukwu *et al.*,¹³⁻¹⁵ who studied the phytochemical properties of unripe and ripe *C. papaya* in their unfermented state. Additionally, the FUP possessed more of the phytochemicals than the FRP contributing to reasons why most studies and treatment are focused on the unripe fruit.^{21,25} The ripe fruit had more of glycosides indicating its use in the treatment of congestive heart failure and less in the unripe, also indicating its use in the management of hypoglycaemia.¹²

Body Weight Gain and Stomach Weight

Ibuprofen is the most often used and prescribed nonsteroidal anti-inflammatory medicines (NSAID).²⁶ It has the potential of causing GIT bleeding, increasing the risk of

gastric ulcers, renal failure, epistaxis,²⁷⁻²⁹ apoptosis,³⁰ heart failure, hyperkalaemia, confusion and bronchospasm.³¹ Previous studies have shown loss of body weight as a symptom in relation chronic NSAID use. Based on body weight data in this study, IBU-intake brought about a statistically significant weight loss likewise an observed deterioration of stomach weight when compared with control and other treatment groups however, experimental rats in protective and therapeutic *C. papaya* treated group gained both body and stomach weight, when compared to IBU-intake group. A previous study done by Nghonjuy *et al.*, where *C. papaya* was administered to poultry animals infected with *Eimeria* oocysts as an anti-coccidial agent showed an increase in weight when compared with negative control.³²

In comparison to omeprazole therapy, a notable reduction in body weight was seen in this study following the various mode of *C. papaya* treatment except in pre-treated with FUP (G6) that exhibited a statistically significant increase when compared with control and omeprazole therapy. Our finding was correlated to the previous reports of Duru and cohort who stated that the observed loss in body weight could be as a result of the androgenic activity of *C. papaya* peel in the body of these rats.³³ Also, a study by Adeneye *et al.*, showed that the pattern of weight gain decreases with progressive increasing dose of the *C. papaya* extract when compared with control rats.³⁴ Their study indicated that *C. papaya* extract can therefore be used to control obesity. Additionally, omeprazole therapy also brought about weight loss when compared to control group, which is in line with the work done by Cui *et al.*, who showed that omeprazole treatment reduced body weight and bone mass gain in young male rats.³⁵ However, protective and therapeutic intervention with FUP and FRP extracts following IBU treatment, progressively improves the food

consumption rate of Wistar rats which relates to the slight increase of body weight gain and stomach weight as well. Comparing the positive effects of FUP and FRP extracts with OME, there was no significant difference in body weight except G6 treated Wistar rats, of which significantly increased when compared with OME (G7) treated rats. Quite similar, the stomach weight progressive improvement across intervention groups revealed no statistically significant difference.

Stomach Ulcers Parameters

Biochemical assessment of total gastric acidity and mucosal integrity is commonly used to determine the state of the stomach after exposure to pharmacological drugs. The acidity level and volume of gastric secretions in the stomach are determined by its pH. A low pH value indicates a decrease in hydrogen ion concentration in gastric juice. Experimentally, this has been linked to the pathogenesis of ulcers and gastric damage.

In this study, the increase in ulcer index and no ulcer inhibition following IBU treatment clearly explained the compromise in the integrity of the mucosal protection, correlating the damages caused by IBU (400mg/kg) administration to induce stomach ulcer. This agrees with previously published studies.^{36,37} Also, a statistically significant increase in total gastric acidity was observed while the stomach pH revealed a non-statistically significant reduction following oral IBU treatment. These detrimental consequences may be attributed to the generation of free radicals or the commencement of a pro-inflammatory response in the stomach. Our findings agreed with previous reports, where indomethacin caused alterations in gastric secretions of Wistar rat's models.³⁸⁻⁴⁰ On the contrary, protective and therapeutic treatment with the two extracts significantly ameliorated these probed parameters. Hence, the effects of the two extracts on ulcer index compared favourably to both the normal control and omeprazole (the standard medicine) utilized in this investigation, indicating that they may have gastroprotective properties.

Stomach Oxidative Stress and Antioxidant Response

Cells/tissues are stable when their rates of free radical production and scavenging capabilities are mostly constant and in equilibrium. On the other side, an imbalance between them creates oxidative stress, which further affects cellular function and leads to a variety of clinical diseases. Continuing with the evaluation of the healing mechanisms of the two extracts, anti-oxidant and oxidative stress parameters were also carried out. The generation of reactive oxygen species (ROS) and oxidative damage are crucial steps in the pathogenesis of gastric ulcer.⁴¹ Oxidative stress is a state that has been shown to change a variety of physiological reactions, and it has a role in both psychological and pathological onset of stomach ulcer. Results in this present study showed that IBU-intake significantly encouraged oxidative stress in the stomach of rats when compared to the stomach of rats in other

groups, resulting in the upsurge level of MDA. In furtherance, SOD and Catalase have been shown to catalyze the elimination of free radicals, lowering their reactive potentials and thereby preventing oxidative cytotoxicity. Results in this present study shows that IBU-intake significantly discouraged the activities of antioxidant enzymes in the stomach of rats when compared to the stomach rats in other groups, resulting in lower levels of SOD and Catalase.

The higher concentration of MDA in the stomach of Ibuprofen-ulcerated rats, as well as the lowered activity of SOD and Catalase, is a result of accelerated lipid peroxidation and overproduction of free radicals, culminating in mucosal injury. Free radicals prevent antioxidant enzymes from working and cause lipid peroxidation, which is a key step in the toxicity mechanism of ibuprofen. However, the ability of fermented *C. papaya* extracts to act in favour of antioxidant defences was determined. Treatment with the two extracts in the protective and therapeutic intervention was able to restore the SOD and Catalase activity and reduce MDA level. In fact, the effects of the two extracts on Catalase and MDA expression, compared favourably to both the normal control and omeprazole (the standard medicine) utilized in this investigation. These findings clearly suggest that the reduction in oxidative damage and enhancement of antioxidant enzymes can be significantly correlated to the antioxidant and anti-inflammatory properties of fermented *C. papaya* extract.

Stomach Anatomy

Ibuprofen (IBU) induced stomach damage can be defined by hemorrhage, edema, inflammatory infiltration, and loss of epithelial cells which can be observed through microscopic examination.⁴² Stomach sections of rats given IBU showed severe degenerated architecture, indicating total ulceration of the submucosa layer which is consistent with previous reports.^{37,43} Studies suggested that ibuprofen could induce apoptosis in gastric mucosal cells, due to increased leukocyte infiltration into the gastric mucosa, which is followed by ROS production.⁴⁴ Damage to the cell is said to be caused by expression of ROS which is a principal factor in NSAID induced gastric ulceration. Thus, the present study confirmed the characteristics of damages caused by ibuprofen on the gastric mucosa. However, protective and therapeutic intervention with the two extracts following IBU treatment, progressively improved the stomach anatomical alterations. These groups showed significant protection against the formation of gastric lesions and edema in the submucosa compared to the animals receiving no medicinal intervention after ulcer induction, though, the most potent protection was seen in FUP pre-treated. Comparing the intervention effects of the two extracts to the animals receiving standard medicinal intervention (omeprazole) after ulcer induction, the most potent protection was seen in FUP pre-treated, which is similar to the control rats used in this investigation. These findings clearly suggest that



fermented unripe *C. papaya* could be used as a safe, highly effective and cheap herbal remedy in treating stomach ulcer when compared to some standard medicinal interventions.

In summary, the protective effects of the two *C. papaya* extracts against ibuprofen-induced stomach ulcers could be attributed to phytometabolite components' favourable therapeutic properties.

CONCLUSION

Generally, the mitigation of stomach ibuprofen insults by oral therapy of the two fermented *C. papaya* extracts is suggestive of their excellent gastroprotective, anti-inflammatory and antioxidative potentials in Wistar rat models. Our study results, though substantial, is by no means exhaustive as some limitations were encountered. We therefore recommend that further advanced investigation of the two fermented *C. papaya* extracts is sorely needed.

Acknowledgment: The Department of Anatomy, Faculty of Basic Medical Science, PAMO University of Medical Sciences (PUMS), for providing a conducive learning and research environment for this project.

REFERENCES

- Narayanan M, Reddy KM, Marsicano E. Peptic ulcer disease and Helicobacter pylori infection. Missouri medicine. 2018; 115(3): 219.
- Sørreide K, Thorsen K, Harrison EM, Bingener J, Møller MH, Ohene-Yeboah M, Sørreide JA. Perforated peptic ulcer. The Lancet. 2015; 386(10000): 1288-98.
- Kuna L, Jakab J, Smolic R, Raguz-Lucic N, Vcev A, Smolic M. Peptic ulcer disease: a brief review of conventional therapy and herbal treatment options. Journal of Clinical Medicine. 2019; 8(2): 179.
- Bi WP, Man HB, Man MQ. Efficacy and safety of herbal medicines in treating gastric ulcer: a review. World journal of Gastroenterology. 2014; 20(45): 17020–17028.
- Singh SP, Kumar S, Mathan SV, Tomar MS, Singh RK, Verma PK, Acharya A. Therapeutic application of Carica papaya leaf extract in the management of human diseases. DARU Journal of Pharmaceutical Sciences 2020; 28(2): 735-744.
- Chen S, Song, J, Sun C, Xu J, Zhu Y, Verpoorte, R, Fan TP. Herbal genomics: examining the biology of traditional medicines. Science. 2015; 347(6219): 27-529.
- Brown ED, Wright GD. Antibacterial drug discovery in the resistance era. Nature. 2016;529(7586):336-343.
- Newman DJ, Cragg GM. Natural products as sources of new drugs from 1981 to 2014. Journal of Natural Products 2016; 79(3): 629-661.
- Robinson MR, Zhang X. The World Medicine Situation (Traditional Medicines: Global Situation, Issues and Challenges). Geneva. World Health Organization, Geneva, Switzerland. 2011.
- Siriwardhana N, Kalupahana NS, Cekanova M, LeMieux M, Greer B, Moustaid-Moussa N. Modulation of adipose tissue inflammation by bioactive food compounds, The Journal of Nutritional Biochemistry. 2013; 24(4): 613-623.
- Gökmen V. Acrylamide in food: Analysis, Content and Potential Health Effects. Academic Press. 2015.
- Eke ON, Augustine AU, Ibrahim HF. Qualitative Analysis of Phytochemicals and Antibacterial Screening of Extracts of Carica papaya Fruits and Seeds. International Journal of Modern Chemistry. 2014; 6(1): 48-56.
- Dada FA, Nzewuji FO, Esan A, Oyeleye S, Adegbola VB. Phytochemical and Antioxidant Analysis of Aqueous Extracts of Unripe Pawpaw (Carica Papaya Linn.) Fruit's Peel and Seed. International Journal of Research and Reviews in Applied Sciences. 2016; 27(3): 68-71.
- Prabhu AK, Devadas SM, Lobo R, Udupa P, Chawla K, Ballal M. Antidiarrheal activity and phytochemical analysis of Carica papaya fruit extract. Journal of Pharmaceutical Sciences and Research. 2017; 9(7): 1151-1155.
- Oluchukwu N, Amaechi A, Akpovbovbo D. Phytochemical Examination of Carica Papaya L. against Callosobruchus M aculatus F. in Stored Bean Seeds. Futo Journal Series. 2021; 5(1): 210-218.
- Elumalai EK, Ramachandran M, Thirumalai T, Vinothkumar P. Antibacterial activity of various leaf extracts of Merremia emarginata. Asian Pacific Journal of Tropical Biomedicine. 2011; 1(5): 406–408.
- Ayo RG. Phytochemical constituent and bioactive of the extract cassia Nigerians vali: A review. Journal of Medicinal Plants Research. 2010; 4(14): 1339-1348.
- Wadekar AB, Nimbawar MG, Panchale WA, Gudalwar BR, Manwar JV, Bakal RL. Morphology, phytochemistry and pharmacological aspects of Carica papaya, a review. GSC Biological and Pharmaceutical Sciences. 2021; 14(3): 234-248.
- Karunamoorthi K, Kim HM, Jegajeevanram K, Xavier J, Vijayalakshmi J. Papaya: A gifted nutraceutical plant-a critical review of recent human health research. CELLMED. 2014; 4(1): 2-1.
- Ezike AC, Akah PA, Okoli CO, Ezeuchenne NA, Ezeugwu S. Carica papaya (Paw-Paw) unripe fruit may be beneficial in ulcer. Journal of Medicinal Food. 2009; 12(6): 1268–1273.
- Owoyele BV, Gbago AF, Ashaolu OS. Gastroprotective effects of aqueous extract of unripe carica papaya fruit in rats. Pacific Journal of Medical Sciences. 2013; 11(2): 3-11.
- Main HM, Whittle JR. Investigation of the vasodilator and antisecretory role of prostaglandins in the rat gastric mucosa by use of non-steroidal anti-inflammatory drugs. British Journal of Pharmacology 1975; 53(2): 217-224.
- Mekonnen AN, Asrade S, Wahab MA. Evaluation of Antiulcer Activity of 80% Methanol Extract and Solvent Fractions of the Root of Croton macrostachyus Hocsht: Ex Del. (Euphorbiaceae) in Rodents. Evidence-Based Complementary and Alternative Medicine. 2020
- Roshan A, Verma NK, Gupta A. A brief study on Carica Papaya-a review. International Journal of Current Trends in Pharmaceutical Research. 2014; 2(4): 541-550.
- Chukwuka KS, Iwuagwu M, Uka UN. Evaluation of nutritional components of Carica papaya L. at different stages of



- ripening. International Organization of Scientific Research (IOSR) Journal of Pharmacy and Biological Sciences. 2013; 6(4): 13-16.
26. Abraham P, Indirani K, Desigamani K. Nitro-arginine methyl ester, a non-selective inhibitor of nitric oxide synthase reduces ibuprofen-induced gastric mucosal injury in the rat. *Digestive Diseases and Sciences*. 2005; 50(9): 1632-1640.
 27. Kennedy MJ. Inflammation and cystic fibrosis pulmonary disease. *Pharmacotherapy: The Journal of Human Pharmacology and Drug Therapy*. 2001; 21(5): 593-603.
 28. Fulcher EM, Soto CD, Fulcher RM. Medications for disorders of the musculoskeletal system. In: *Principles and Applications. A work text for allied health professionals*. Saunders, an imprint of Elsevier Science Philadelphia. 2003; 510.
 29. Gambero A, Becker TL, Zago AS, Oliveira AF, Pedrazzoli J. Comparative study of anti-inflammatory and ulcerogenic activities of different cyclo-oxygenase inhibitors. *Inflammopharmacology*. 2005; 13(5): 441-454.
 30. Durkin E, Moran AP, Hanson PJ. Apoptosis induction in gastric mucous cells in vitro: lesser potency of *Helicobacter pylori* than *Escherichia coli* lipopolysaccharide, but positive interaction with ibuprofen. *Journal of Endotoxin Research*. 2006; 12(1): 47-56.
 31. Rossi S. *Australian medicine hand book* ISBN. 2004; 0-9578521-4-2.
 32. Nghonjuyi NW, Tiambo CK, Kimbi HK, Manka'a CN, Juliano RS, Lisita F. Efficacy of ethanolic extract of *Carica papaya* leaves as a substitute of sulphonomide for the control of coccidiosis in KABIR chickens in Cameroon. *Journal of Animal Health and Production*. 2015; 3(1): 21-27.
 33. Duru KC, Amadi BA, Amadi CT, Lele KC, Anudike JC, Chima-Ezika OR, Osuocha K. Toxic effect of *Carica papaya* bark on body weight, haematology, and some biochemical parameters. *Biokemistri*. 2012; 24(2): 67-71.
 34. Adeneye AA, Olagunju JA. Preliminary hypoglycemic and hypolipidemic activities of the aqueous seed extract of *Carica papaya* Linn in Wistar rats. *Biology and Medicine*. 2009; 1(1): 1-10.
 35. Cui GL, Syversen U, Zhao CM, Chen D, Waldum HL. Long-term omeprazole treatment suppresses body weight gain and bone mineralization in young male rats. *Scandinavian Journal of Gastroenterology*. 2001; 36(10): 1011-1015.
 36. Narayan S, Devi RS, Srinivasan P, Shyamala CS. *Pterocarpus santalinus*: a traditional herbal drug as a protectant against ibuprofen induced gastric ulcers. *Phytotherapy Research: PTR*. 2005; 19(11): 958-962.
 37. Liu J, Sun D, He J, Yang C, Hu T, Zhang L, Zheng Y. Gastroprotective effects of several H2RAs on ibuprofen-induced gastric ulcer in rats. *Life Sciences*. 2016; (149): 65-71.
 38. Adhikary B, Yadav SK, Roy K, Bandyopadhyay SK, Chattopadhyay S. Black tea and theaflavins assist healing of indomethacin-induced gastric ulceration in mice by antioxidative action. *Evidence-based complementary and alternative medicine*. 2010.
 39. Ashraf MV, Thamocharan G, Sengottuvelu S, Sherief HS, Sivakumar T. Evaluation of anti-ulcer activity of *Ficus pumila* L. leaf extract in albino rats. *Global Journal of Research on Medicinal Plants & Indigenous Medicine*. 2012; 1(8): 340.
 40. Sabiu S, Garuba T, Sunmonu T, Ajani E, Sulyman A, Nurain I, Balogun A. Indomethacin-induced gastric ulceration in rats: Protective roles of *Spondias mombin* and *Ficus exasperata*. *Toxicology reports*. 2015; (2): 261-267.
 41. Naito Y, Takagi T, Handa O, Yoshikawa T. Lipid hydroperoxide-derived modification of proteins in gastrointestinal tract. *Lipid Hydroperoxide-Derived Modification of Biomolecules*. 2014; 137-148.
 42. Uthman ZS, University B. Anti-Ulcerative Effect of Aqueous Extract of *Cucumis Melo* on Non-Steroidal Anti-Inflammatory Drugs (NSAIDS) Induced Gastric Ulceration in Male Wistar Rats. 2020.
 43. Adebayo-Gege GI, Okoli BJ, Oluwayinka PO, Ajayi AF, Fanyana M. Antiulcer and Cluster of Differentiation-31 Properties of *Cucumis melo* L. on Indomethacin-Induced Gastric Ulceration in Male Wistar Rats. In *International Conference on Pure and Applied Chemistry*. 2018; 501-516. Springer, Cham.
 44. Golbabapour S, Hajrezaie M, Hassandarvish P, Abdul N, Hadi HA, Nordin N. Acute toxicity and gastroprotective role of *M. pruriens* in ethanol induced gastric mucosal injuries in rats. *BioMed Research International*. 2013; 1-13.
 45. Goorani S, Zhaleh M, Zangeneh A, Koohi MK, Rashidi K, Moradi R, Zangeneh MM. The aqueous extract of *Glycyrrhiza glabra* effectively prevents induced gastroduodenal ulcers: Experimental study on Wistar rats. *Comparative Clinical Pathology*. 2019;28(2):339-347.

Source of Support: The author(s) received no financial support for the research, authorship, and/or publication of this article.

Conflict of Interest: The author(s) declared no potential conflicts of interest with respect to the research, authorship, and/or publication of this article.

For any question relates to this article, please reach us at: globalresearchonline@rediffmail.com
 New manuscripts for publication can be submitted at: submit@globalresearchonline.net and submit_ijpsrr@rediffmail.com

